

IN DEPTH

Takotsubo Syndrome: Pathophysiology, Emerging Concepts, and Clinical Implications

Trisha Singh¹ , BM; Hilal Khan¹ , MB BCh BAO, MRCP; David T. Gamble, MPharm, MBBS; Caroline Scally, MBChB; David E. Newby¹ , DM, PhD; Dana Dawson¹ , MD, DPhil

ABSTRACT: Takotsubo syndrome is a condition characterized by acute transient left ventricular systolic dysfunction, which at presentation can be challenging to distinguish from acute myocardial infarction. Although previously thought to be a benign, self-limiting condition, recent studies have confirmed that patients with takotsubo syndrome have persistent subtle ongoing cardiac dysfunction, and many continue to have limiting symptoms despite restoration of left ventricular ejection fraction. Moreover, these patients have a substantial burden of morbidity and mortality, as well, with high rates of subsequent major adverse cardiovascular events that approach those of patients with acute coronary syndrome. The mechanisms behind this condition remain elusive. Despite substantial research, the medical community continues to have an incomplete understanding of its underlying pathogenesis and pathophysiology. Catecholamine-induced myocardial injury is the most established and well-known theory, but this does not explain all the clinical features and presentations of the condition, and numerous other pathways and abnormalities are emerging. Because of the poor understanding of its underlying pathophysiology, there is a lack of evidence-based interventions to treat the acute episode, to avoid recurrences, and to prevent major adverse cardiovascular events. This highlights the need for further research to gain a better understanding of the underlying pathophysiology to inform appropriate randomized controlled trials of interventions targeting the causative pathways. Only then can evidence-based management strategies be established to improve clinical outcomes of this potentially lethal condition.

Key Words: physiopathology ■ Takotsubo cardiomyopathy ■ treatment outcomes

*He first deceased; she for a little tried
To live without him; liked it not, and died.*

—Sir Henry Wootton, 1651

Takotsubo syndrome was first named by Sato et al in 1990,¹ although sudden and rapid death after intense psychological stress was described by Engel² and Rees and Lutkins³ >50 years ago. After some initial skepticism, awareness of this potentially fatal condition has substantially increased over the past 10 to 15 years^{4,5} and is now an established increasingly frequent and important cause of acute cardiac presentations.⁵

Takotsubo syndrome has several unique characteristics that distinguish it from other acute cardiac emergencies. It is typified by nonobstructed coronary arteries associated with a characteristic anteroseptal-apical dys-

kinetic ballooning of the left ventricle with hyperkinetic basal segments (Figure 1). These features spontaneously resolve to restore apparently normal left ventricular function.^{6,7} Despite being described 30 years ago, its pathogenesis and pathophysiology remain poorly understood and the lack of treatments often presents a clinical dilemma for physicians. Previously believed to be a benign self-limiting condition,^{8–13} takotsubo syndrome is now known to be associated with substantial short- and long-term morbidity and mortality. The purpose of this review is to provide an update on the current understanding of the clinical features of this condition, to discuss the latest theories regarding its pathogenesis and pathophysiology, and to highlight the need for future therapeutic interventions to reduce and to prevent the major morbidity and mortality.

The opinions expressed in this article are not necessarily those of the editors or of the American Heart Association.

Correspondence to: Trisha Singh, BM, University of Edinburgh, Rm SU. 305, Chancellor's Building, 49 Little France Crescent, Edinburgh, EH16 4SB United Kingdom. Email tsingh@ed.ac.uk

For Sources of Funding and Disclosures, see page 1016.

© 2022 American Heart Association, Inc.

Circulation is available at www.ahajournals.org/journal/circ

EPIDEMIOLOGY

Takotsubo syndrome is increasing in incidence, which may reflect the rising prevalence of modern life stressors and the greater awareness and detection of the condition by the clinical cardiology community, as well.^{5,9} Takotsubo syndrome accounts for ≈2% to 3% of all patients and 5% to 6% of female patients presenting with acute coronary syndrome,^{9,14,15} although it may be underappreciated and underdiagnosed especially in patients who have coexisting coronary artery disease.¹⁶

Whereas the condition can occur in any age group, it characteristically affects women in the sixth decade of life, although patients <50 years of age account for ≈10% of cases.¹⁷ Younger patients are more likely to be male, or have atypical takotsubo, fewer comorbidities, and acute neurological or psychiatric disorders, and to develop in-hospital complications.¹⁷

Although increasing age may be a risk factor for developing takotsubo syndrome,¹⁵ the underlying mechanism remains unknown, but can be explained in part by the influences of age and sex on the sympathetic nervous system. Sympathetic nervous system activity increases with age, particularly in women, and cardiac sympathetic stimulation is augmented because of an imbalance in neuronal norepinephrine homeostasis.^{18,19} With age, there is a decrease in vagal tone and baroreflex sensitivity with a concomitant increase in sympathetic activation,¹⁸ potentially rendering the myocardium more susceptible to enhanced levels of catecholamines. Although increasing age may be a risk factor for developing takotsubo syndrome, it is not an independent risk factor for in-hospital mortality which contrasts with the well-recognized age-related mortality seen in patients with acute coronary syndrome.⁹

Although most patients (80%–90%) who develop takotsubo syndrome are women,^{15,20} the mechanism underlying this large sex disparity is unknown. Several hypotheses have been proposed and centered on estrogen deprivation occurring postmenopause and its role in regulating sympathetic drive and microvascular blood flow through endothelium-dependent and -independent mechanisms.

Familial takotsubo syndrome has been described,²¹ although multigenerational Mendelian inheritance does not occur, suggesting that a genetic predisposition may interact with environmental factors or have a polygenic cause. Polymorphisms of the β_1 - and β_2 -adrenoreceptor genes have been associated with reduced left ventricular function in patients with takotsubo syndrome, but results are conflicting and inconclusive.^{22,23} Larger studies are currently underway to explore potential genetic associations (GENETIC [Is There a Genetic Predisposition for Acute Stress-induced {Takotsubo}Cardiomyopathy], NCT04513054).

NATURAL HISTORY

Takotsubo syndrome had previously been viewed as an interesting anomaly that ran a benign course. As such, patients were often given reassurances that they were fortunate not to have had a heart attack, and that their heart would recover completely back to normal with an excellent prognosis. However, we now know this is not the case. Despite the recovery of the left ventricular ejection fraction and the absence of major coronary artery disease, patients with takotsubo syndrome have outcomes that are considerably worse than the general population.^{8–13} Takotsubo syndrome has an in-hospital mortality that is comparable to acute ST-segment-elevation myocardial infarction.^{9–11,13} Beyond the acute event, patients with takotsubo syndrome have a rate of all-cause death of 5.6% per patient-year and a rate of major adverse cardiac and cerebrovascular events of 9.9% per patient-year.⁹

As many as 1 in 8 patients will experience a repeat acute takotsubo syndrome episode within 5 years of the index event,^{24,25} often precipitated by a further (and often different) stressful event, although no known clinical or psychological factors can predict the likelihood of recurrence. Moreover, many patients report substantial morbidity after takotsubo syndrome. Symptoms of dyspnea, lethargy, palpitations, and fleeting chest pains can persist for ≥2 years after the index event despite the normalization of the left ventricular ejection fraction. Thus, there is a substantial burden of long-term morbidity and mortality associated with takotsubo syndrome.

CLINICAL FEATURES

Patients with takotsubo syndrome classically present with acute-onset chest pain, dyspnea, and changes on the ECG occurring in association with an acute stressful event.¹⁵ This presentation mimics, and is often initially managed as, an acute coronary syndrome (Table 1). When marked, it can include presentations consistent with an acute ST-segment-elevation myocardial infarction. In extreme circumstances, patients can present with severe heart failure, cardiogenic shock, or arrhythmias requiring hemodynamic and sometimes ventilatory support.

A precipitating stressful event is typically considered to be unexpected bereavement, conflict, or a major life event. However, it is important to appreciate that one-third of patients do not recognize an identifiable stressor, and this is reflected in the latest diagnostic criteria.¹⁵ This figure may be an overestimate because some patients may be reluctant to discuss personal stressful circumstances, or clinicians may not fully explore or probe underlying stress-related or mental health problems. Furthermore, protracted previous

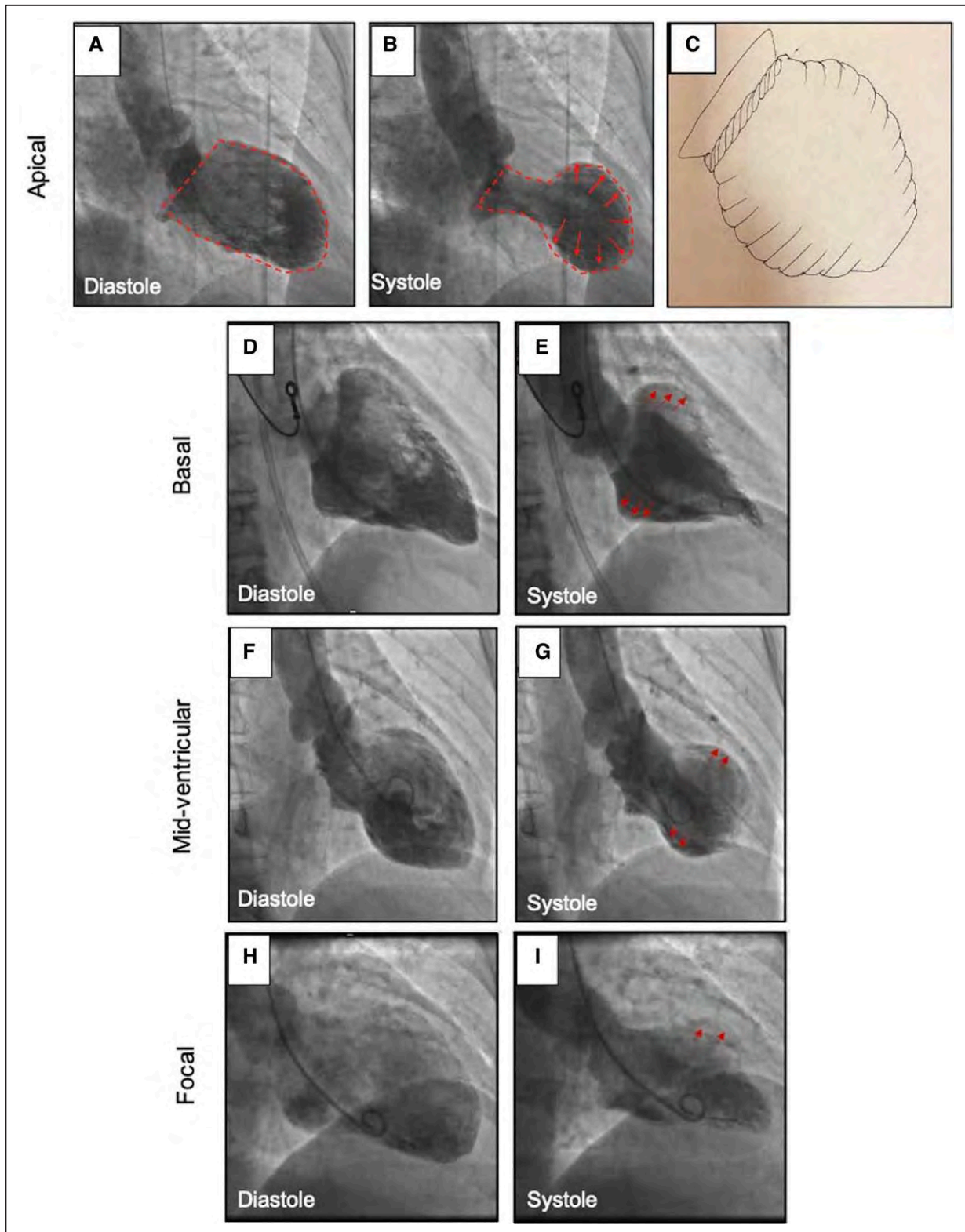


Figure 1. Takotsubo syndrome: anatomic variants.

Left ventriculogram demonstrating apical (**A** and **B**) ballooning of the left ventricle, similar to the shape of a Japanese octopus trap (**C**). Basal (**D** and **E**), midventricular (**F** and **G**), and focal (**H** and **I**) variations of takotsubo syndrome.

stress may contribute, and this is often undisclosed and underappreciated. Takotsubo syndrome can also be precipitated after major events resulting in community

stress, such as earthquakes (New Zealand 2010, 2011, and 2016),²⁶ and more recently, anxiety related to the COVID-19 pandemic.²⁷

Table 1. Differential Diagnosis in Takotsubo Syndrome

	Takotsubo syndrome	Myocardial infarction with non-obstructive coronary arteries	Type 2 myocardial infarction	Type 1 myocardial infarction
Characteristic clinical features	Acute chest pain or dyspnea Preceding stressor* Can be associated in the context of other illness Preexisting psychiatric illness	Acute chest pain Varies depending on underlying pathology Requires clinical evidence of myocardial infarction	Acute chest pain Supply or demand imbalance Tachycardia or hypotension Concomitant illness Usually have comorbidities	Acute chest pain Traditional cardiovascular risk factors
Investigations				
ECG	Widespread ST-segment or T-wave abnormality QTc prolongation (late)	New ischemic changes	New ischemic changes Tachycardia	Territorial ST-segment or T-wave abnormality
Blood test results	Moderate cardiac troponin elevation Marked B-type natriuretic peptide, and C-reactive protein elevation	Elevated troponin >99th centile	Elevated troponin >99th centile	Marked cardiac troponin elevation Moderate B-type natriuretic peptide, and C-reactive protein elevation
Echocardiography	Temporary left ventricular dysfunction regional wall motion abnormality depending on subtype of takotsubo (apical, basal, focal)	Normal or persistent left ventricular impairment Regional wall motion abnormality	Normal or persistent left ventricular impairment May have regional wall motion abnormality	Normal or persistent left ventricular impairment regional wall motion abnormality
Coronary angiography	Normal or nonobstructive coronary artery disease Apical ballooning on left ventriculogram	Normal or nonobstructive coronary artery disease Evidence of acute plaque rupture on intravascular ultrasound or optical coherence tomography	Normal, nonobstructive or obstructive coronary artery disease	Obstructive disease
MRI	No persistent late gadolinium enhancement Elevated native T1/T2	Late gadolinium enhancement Regional wall motion abnormality	Normal or late gadolinium enhancement May have regional wall motion abnormality	Late gadolinium enhancement-infarct pattern Elevated native T1/T2 Regional wall motion abnormality

MRI indicates magnetic resonance imaging.

*Not always present.

Noncardiac medical conditions, in particular, neurological, such as intracranial hemorrhage, pheochromocytoma, and epilepsy, or severe acute critical illnesses can induce takotsubo syndrome.^{28–30} Cancer is increasingly recognized as a precipitant, and this may relate to the direct mental stress from receiving a diagnosis of malignancy or the combined mental and physical stress of cancer treatments.³¹ Stresses from a range of physical illnesses or procedures are also recognized and include acute exacerbations of asthma or chronic obstructive pulmonary disease, endoscopic examinations, cardioversions, and many others.

Acute or chronic mental health conditions, such as depression and anxiety, are present in one-third of patients with takotsubo syndrome.^{8,9,32} Rates of psychiatric or neurological disorders are 7-fold higher than in patients with acute coronary syndrome, with a high prevalence of type-D personality characteristics (negative emotions, social inhibition) suggesting a predisposing element that has not been fully explored by psychiatrists or clinical psychologists.³³ Patients affected by depression and anxiety also demonstrate overactivity of the sympathetic nervous system in response to physical or emotional stress, implying greater susceptibility to takotsubo syndrome.³³

The multicenter Spanish RETAKO (Registry for Takotsubo syndrome)¹⁰ and Inter-TAK (the International Takot-

subo Registry)^{11,32} have shown that patients with an emotional stressor are more likely to be female, present with chest pain, and have better outcomes. Those with a physical stressor (infection, surgery, trauma, neurological disorder, and hypoxia) are more likely to be men, have comorbidities, present with syncope and dyspnea, develop the basal pattern of left ventricular dysfunction, and have acute complications.^{8,10,32}

INVESTIGATIONS

The investigation of takotsubo syndrome may occur either because it is the primary suspected diagnosis or, more commonly, after an initial investigation for acute coronary syndrome attributable to the marked overlap in clinical presentation. A multimodal imaging approach is often needed to discriminate between the differential diagnoses of the acute cardiac presentation (Table 1), with cardiac magnetic resonance playing an increasingly important role.³⁴

Electrocardiogram

The ECG commonly demonstrates acute dynamic changes at presentation, resembling those of an acute coronary syndrome.²⁵ The most common abnormalities are ST

elevation, T-wave inversion, and left bundle-branch block. ST elevation and T-wave inversion are widespread and may not localize to a particular territory.^{35,36} Three evolving electrocardiographic stages of takotsubo syndrome have been described. Stage 1 involves ST deviation occurring within the first few hours of symptoms onset.³⁶ Stage 2 involves progressive deep T-wave inversion and QTc prolongation, occurring within 1 to 3 days and peaking at 2 to 6 days, although when corrected for sex, the QTc is not different from male patients with acute myocardial infarction.³⁷ These T-wave inversions are usually widespread over the precordial (V₁ through V₆), bipolar (I, II), and lateral limb (aVL) leads and correlate with myocardial edema, which can persist beyond ventricular contractile recovery.³⁶ During these first 24 to 48 hours, torsade de pointes and other ventricular tachycardias can occur. The association of ventricular arrhythmias with prolonged QTc segment in takotsubo syndrome is well established. However, ventricular arrhythmias in the hyperacute phase of takotsubo syndrome are unlikely to be related to QTc prolongation.³⁵ It is also possible that patients present with ventricular arrhythmia and are only subsequently diagnosed with takotsubo syndrome, making it very difficult to understand which occurred first. Stage 3 involves gradual resolution of T-wave and QTc changes over subsequent weeks or months.³⁵ The normalization of myocardial contractile function occurring before long-lasting electrocardiographic abnormalities is in stark contrast to the simultaneous recovery of both contractile function and the ECG seen after restoration of blood flow in ischemic myocardial stunning. Together with a relative absence of isolated ST depression on presentation ECG, these concepts would argue against classical myocardial ischemia playing a part in the pathogenesis of takotsubo syndrome.

Other electrocardiographic findings have also been reported. A J wave and fragmented QRS during the hyperacute period have been described³⁸ and low-voltage QRS complexes, as well. In those presenting with ST-segment elevation, the elevation is more subtle or of lower voltage compared with patients with acute myocardial infarction.³⁵ Q waves may also occur acutely and disappear rapidly with reappearance of the R wave. In conclusion, subtle differences in electrocardiographic changes exist between takotsubo syndrome and acute coronary syndrome. The presence of ST-segment elevation will affect whether the patient undergoes coronary angiography as an emergency, or the procedure is slightly deferred.

Cardiac and Inflammatory Biomarkers

Plasma cardiac troponin concentrations are typically raised, although peak values are lower than in patients with ST-segment-elevation myocardial infarction and are more comparable to those presenting with non-ST

elevation.^{39,40} The rise in cardiac troponin is often disproportionately lower than the associated degree of left ventricular contractile impairment would suggest. This likely reflects the absence of myocardial necrosis, which is more akin to myocardial infarction. In contrast, plasma BNP (B-type natriuretic peptide) and NT-proBNP (its N-terminal inactive molecule) concentrations are typically much higher than those seen in patients with myocardial infarction.^{41,42} Moreover, NT-proBNP concentrations are particularly high in patients with apical compared with atypical variants, which may reflect the greater degree of acute left ventricular dilatation and myocardial stretch.

Several proinflammatory (interleukin-2, interleukin-4, interleukin-8, interferon and tumor necrosis factor- α) and anti-inflammatory (interleukin-10) cytokines are raised at presentation and can continue to remain elevated for several months thereafter, reflecting the inflammatory pathophysiology of takotsubo syndrome.⁴³ It is interesting that interleukin-6 concentrations tend to be higher in patients with acute coronary syndrome, potentially reflecting the greater extent of myocardial necrosis.⁴⁴

Coronary Angiography and Left Ventriculography

The diagnosis of takotsubo syndrome is often made once an invasive coronary angiogram has been performed and normal or nonobstructive coronary artery disease documented. Coexisting coronary artery disease is present in $\approx 15\%$ of patients with takotsubo syndrome,^{10,13} and careful correlation between angiography and the wall motion abnormalities is required. Where doubt exists, advanced intravascular imaging techniques, such as optical coherence tomography and intravascular ultrasound, may help to exclude plaque rupture, which is not a characteristic of takotsubo syndrome.⁴⁵ Other types of myocardial infarction with nonobstructive coronary artery disease or spontaneous coronary artery dissection also require exclusion in the basis of careful inspection of the coronary angiogram in combination with cardiac magnetic resonance imaging.

Left ventriculography usually confirms the diagnosis because of the characteristic ballooning of the left ventricle. In the majority (50%–80%) of cases, there is a typical pattern of apical and midventricular dyskinesia, akinesia, or hypokinesia with basal sparing (Figure 1).¹⁵ The second most common form affects the midventricle as a circumferential midventricular wall motion abnormality with basal and apical hyperkinesia; this pattern is pathognomonic for takotsubo syndrome (Figure 1).⁴⁶ Patients may occasionally present with a reverse takotsubo syndrome where the basal segments are affected with sparing of the mid and apical segments. The incidence of right ventricular involvement can vary (10%–30%) and is associated with more severe disease and complications. Last, other rarer variants have been described, involving

isolated right ventricular or focal (segmental) left ventricular takotsubo syndrome.⁴⁷

Echocardiography

Echocardiography can be used to help support the diagnosis (extent, severity, and location of the wall motion abnormalities) and to identify potential complications of takotsubo syndrome. Approximately 20% of patients have evidence of left ventricular outflow tract obstruction.⁴⁸ This usually occurs in patients with the typical apical to mid cavity ballooning with basal hyperkinesia and can be associated with mitral regurgitation secondary to systolic anterior motion of the mitral valve apparatus. Ultrasound contrast agents can be useful to delineate wall motion abnormalities and assess for left ventricular thrombus formation, which can occur acutely or later in the disease course.⁴⁹ More advanced techniques, such as speckle-tracking echocardiography, can also show abnormalities of left ventricular twist and lower mean values of systolic peak velocity, strain, and strain rate.⁵⁰ Although left ventricular twist and deformation indices typically improve during the recovery phase, persistently abnormal cardiac deformation indices suggest a phenotype of heart failure with preserved ejection fraction.⁵¹

Cardiac Magnetic Resonance

Cardiac magnetic resonance with gadolinium contrast administration distinguishes takotsubo syndrome from acute myocardial infarction and myocarditis.⁵² Unlike these latter conditions, fibrosis depicted by late gadolinium enhancement is usually not a feature of takotsubo syndrome. A characteristic pattern of takotsubo syndrome rarely appears as a thin transmural band of fibrosis at the hinge points between the hyperkinetic base and dyskinetic apex or midcavity. This can be seen both acutely (at the time of presentation) and 4 to 5 months later at follow-up (Figure 2). This possibly results from the opposing strong shear forces applied to the left ventricular wall. Cardiac magnetic resonance also provides a reliable assessment of right ventricular involvement, identification of left and right ventricular thrombi, and often shows the presence of a small pericardial effusion (and pleural effusions, as well), in particular, if the test is performed early after presentation.

Intense myocardial edema is an important feature of takotsubo syndrome (Figure 2). Edema is not only confined to regions of abnormal contractility but is present to a lesser extent within the entirety of the ventricular myocardium. Myocardial edema resolves gradually over weeks or months after the index event, typically taking much longer to recover than myocardial contractility.⁵³ Reflecting this, left ventricular mass is markedly elevated and native T1 and T2 mapping values are increased during the acute phase, gradually resolving over 5 to 6

months during convalescence (Figure 2).⁵¹ Both myocardial edema and acute inflammation are detectable at presentation, but it remains unclear whether they are a consequence of takotsubo syndrome or if they represent a primary, causal inflammatory stimulus.

DIAGNOSTIC CRITERIA

The diagnosis of takotsubo syndrome can be challenging because the clinical features have many similarities with acute coronary syndrome, and immediate early cardiac imaging is needed because of the rapid normalization of the left ventricular ejection fraction. The most widely used diagnostic criteria are those proposed by the Mayo Clinic in 2004⁵⁴ and subsequently revised in 2008⁵⁵ (Figure 3). Other groups have proposed slightly different diagnostic conventions, such as the Gothenburg criteria,⁵⁶ Johns Hopkins criteria,⁵⁷ the Takotsubo Italian Network proposal,⁵⁸ and the Heart Failure Association Takotsubo Syndrome Taskforce of the European Society of Cardiology criteria.⁵⁹ The underlying principle is that takotsubo syndrome is a diagnosis of exclusion because a specific diagnostic test or biomarker has yet to be defined to identify the condition. This extends to the postmortem examination of fatal cases where specific diagnostic pathological features have yet to be defined, making it currently impossible to assign this diagnosis at autopsy.

The presence of coronary artery disease may traditionally have deterred the clinician from a diagnosis of takotsubo syndrome. Despite this uncertainty, it has become evident that takotsubo syndrome can coexist in the presence of fixed coronary artery disease and can even be triggered by acute coronary syndrome.¹⁵ It is vital to look for subtle differences in clinical presentation to avoid misdiagnosis (Table 1). Likewise, patients may be incorrectly diagnosed with takotsubo syndrome if coronary angiography reveals nonobstructive coronary artery disease, and the possibility of plaque rupture has not been ruled out, especially because stressful events are also associated with acute plaque rupture and type 1 myocardial infarction. The Inter-TAK diagnostic score⁶⁰ was developed to aid the clinician in distinguishing takotsubo syndrome from acute coronary syndrome, but its performance is variable. Because understanding of the fundamental pathophysiology of takotsubo syndrome is limited, these criteria are likely to continue to evolve with time. We provide a diagnostic pathway incorporating the Inter-TAK score to aid diagnosis (Figure 3). The hallmark of the takotsubo syndrome is ultimately the reversibility in systolic function that occurs within hours, days, or weeks, in the absence of infarct-specific myocardial fibrosis.^{6,14} The clinical implication of recovery time remains unknown, and there is emerging evidence that full recovery may be slower and less complete than initially thought.

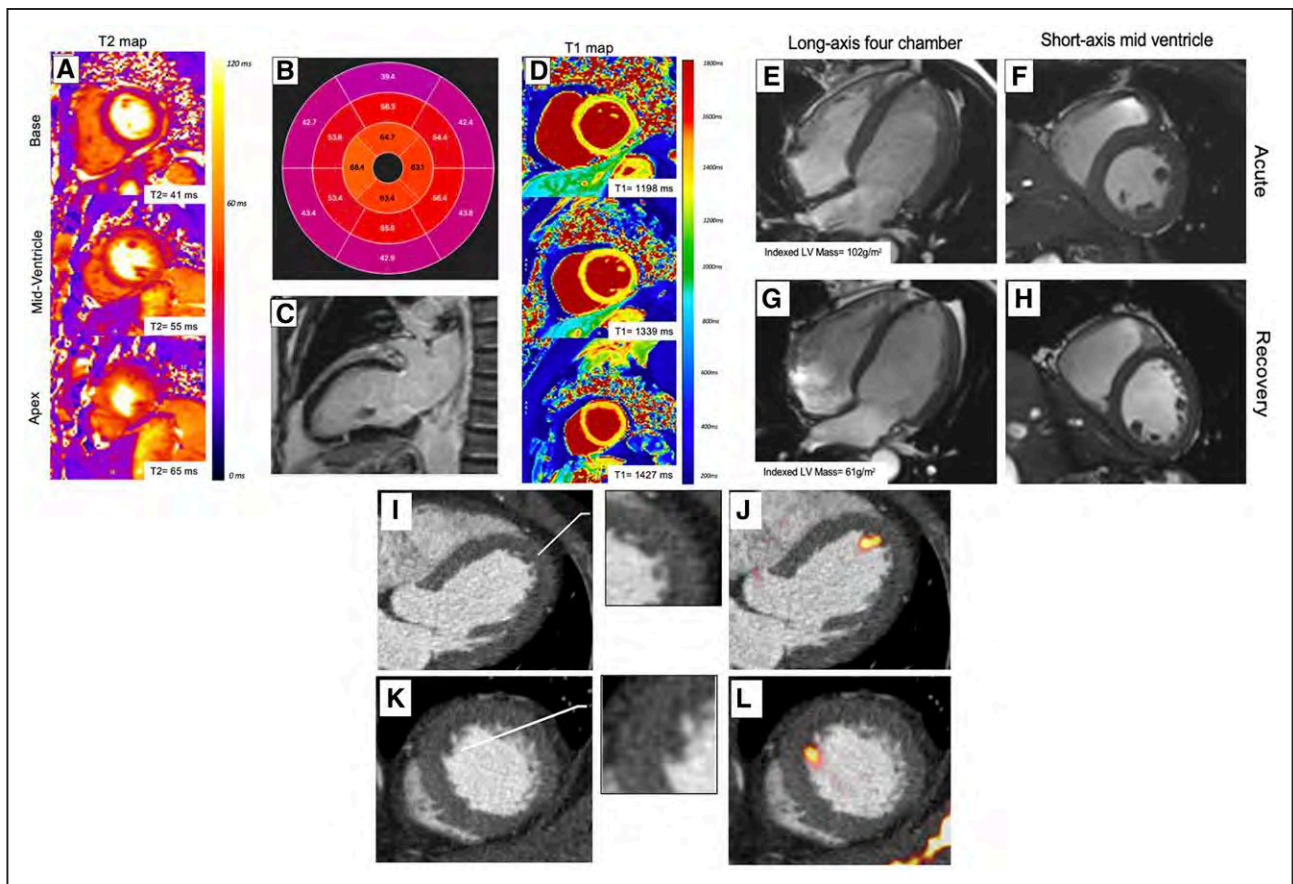


Figure 2. Cardiac magnetic resonance imaging and computed tomography findings in takotsubo syndrome.

Short-axis T2 maps (A), T2 polar map (B), and short-axis T1 maps (D), demonstrating elevated T2 and T1 values circumferentially in the mid and apical regions (outside a coronary territory). C, Long-axis 2-chamber view demonstrating transmural fibrotic band pattern typical of takotsubo syndrome 4 months after the index event. Long-axis 4-chamber and short-axis views of midventricle demonstrating elevated left ventricular mass in acute phase (E and F) and normalization during convalescence (G and H). Hybrid positive emission tomography with cardiac computed tomography angiography depicting a small left ventricular thrombus in a patient with takotsubo syndrome with no clinically apparent thrombus on conventional imaging. There is subtle hypoattenuation on the computed tomography angiogram (insets) and increased uptake of an activated platelet and thrombus-specific radiotracer (^{18}F -GP-1; yellow-red) in long-axis 4-chamber (I and J) and short-axis (K and L) views on positron emission tomography.

CLINICAL COURSE

Despite its transient nature, patients are at substantial risk of complications during the initial hospitalization period, with 1 in 5 patients at risk of serious adverse events and 1 in 25 dying.⁹ These events occur as a consequence of acute complications from the takotsubo syndrome itself (cardiogenic shock, cardiac arrest, and congestive heart failure) or the critical underlying illness (respiratory failure, acute renal failure, stroke, and sepsis).^{9,10,12,61} The overall rate of in-hospital complications is comparable to that of patients with acute coronary syndrome (21% versus 19%; Figure 4).^{9,11,13}

Fifteen percent to 20% of patients with takotsubo syndrome develop hypotension, which varies in severity.⁶¹ Hypotension likely reflects the underlying left ventricular systolic dysfunction, although vasodilatation, left ventricular outflow tract obstruction, and mitral regurgitation may contribute. However, the extent and severity of left ventricular systolic dysfunction does

not appear to correlate with systolic blood pressure or clinical heart failure. Patients with apical takotsubo syndrome are more likely to sustain a greater degree of left ventricular dysfunction than those with atypical forms. Ten percent of patients with takotsubo syndrome will develop cardiogenic shock, although these rates are surprisingly low given the magnitude and extent of left ventricular systolic dysfunction.⁶¹ Patients who sustain an anterior ST-segment-elevation myocardial infarction and a similar degree of left ventricular systolic dysfunction are often more compromised.

Left ventricular outflow tract obstruction occurs in 10% to 15% of patients and may exacerbate left ventricular apical ballooning and dysfunction because it exposes the apex to higher wall stress than the basal myocardium.⁵⁹ Similarly, mitral regurgitation occurs in 10% to 20% of patients⁶¹ because of tethering and systolic anterior motion of the mitral valve leaflet. These abnormalities resolve with the subsequent associated improvements in left ventricular contractility.

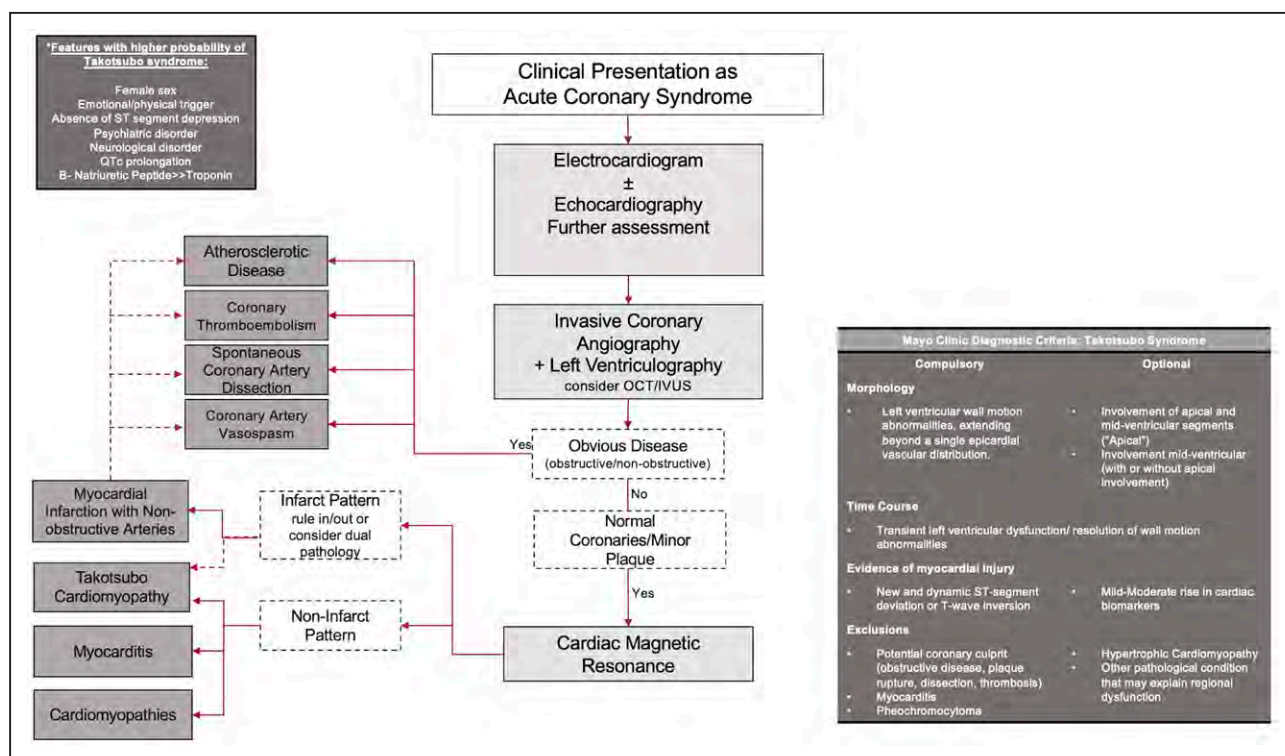


Figure 3. Diagnostic criteria and pathway for takotsubo syndrome.

Atrial and ventricular arrhythmias are seen frequently, with atrial fibrillation being the most common (3%). Life-threatening arrhythmias, such as torsade de pointes and polymorphic ventricular tachycardia, occur occasionally.^{9,13}

Systemic thromboembolism is an important complication of takotsubo syndrome, which is often underappreciated. Rates of ischemic stroke are higher than those seen after an acute coronary syndrome and occur in 1% to 2% of acute hospitalizations.^{9,13,62} An elevated stroke risk appears to extend beyond the acute episode and is much more prominent than subsequent rates of myocardial infarction that are low (1.7% versus 0.3%; Figure 4).⁴⁷ The most likely embolic origin is left ventricular mural thrombus attributable to blood stasis within the akinetic ventricular segments (Figure 2). The spontaneous improvement in left ventricular myocardial function may initiate embolization and consequent stroke. The GEIST registry (German Italian Stress Syndrome) demonstrated that the presence of left ventricular thrombi was associated with embolic cerebrovascular events in 17% of patients.⁴⁹

Several studies^{8–11,13} have demonstrated that long-term mortality is similar to that of acute coronary syndrome: all-cause death in 5.6% of patients per year (Figure 4).⁹ Cardiovascular deaths are the most common cause of death in both takotsubo and acute coronary syndromes.⁸ More recently, Redfors et al¹³ demonstrated that long-term mortality for takotsubo syndrome is comparable to patients with non-ST-segment-elevation myocardial infarction, but lower than those presenting with ST-segment-elevation myocardial infarction. Age <50 years, male sex, physical

trigger, left ventricular ejection fraction <45%, presence of atrial fibrillation, cardiac troponin concentration >10-fold the upper limit of normal, and acute neurological disease were independent predictors of 1-year mortality,^{8–10,12} but not the location (apical, basal, midventricular, focal) of myocardial ballooning.³²

IN-HOSPITAL MANAGEMENT

With no robust or clinical trial evidence available for the treatment of this condition, extrapolation of therapies known to be effective after myocardial infarction, such as β -blocker and angiotensin-converting enzyme inhibitor therapies, have been adopted by some clinicians. In the acute setting, the focus of management relates to supportive care and treatment of complications and is predominantly based on clinical experience and expert consensus (Table 2).^{25,63}

Heart Failure

In the unusual situation where patients present with pulmonary edema, they should be treated with intravenous diuretic and nitrate therapies. Patients who sustain left ventricular outflow tract obstruction may benefit from sequential small doses of short-acting β -blocker therapy,⁶⁴ and small boluses of intravenous fluid, under careful monitoring in a high-dependency care environment, as well.

The management of shock is challenging in both theory and practice. Most inotropic agents can potentially

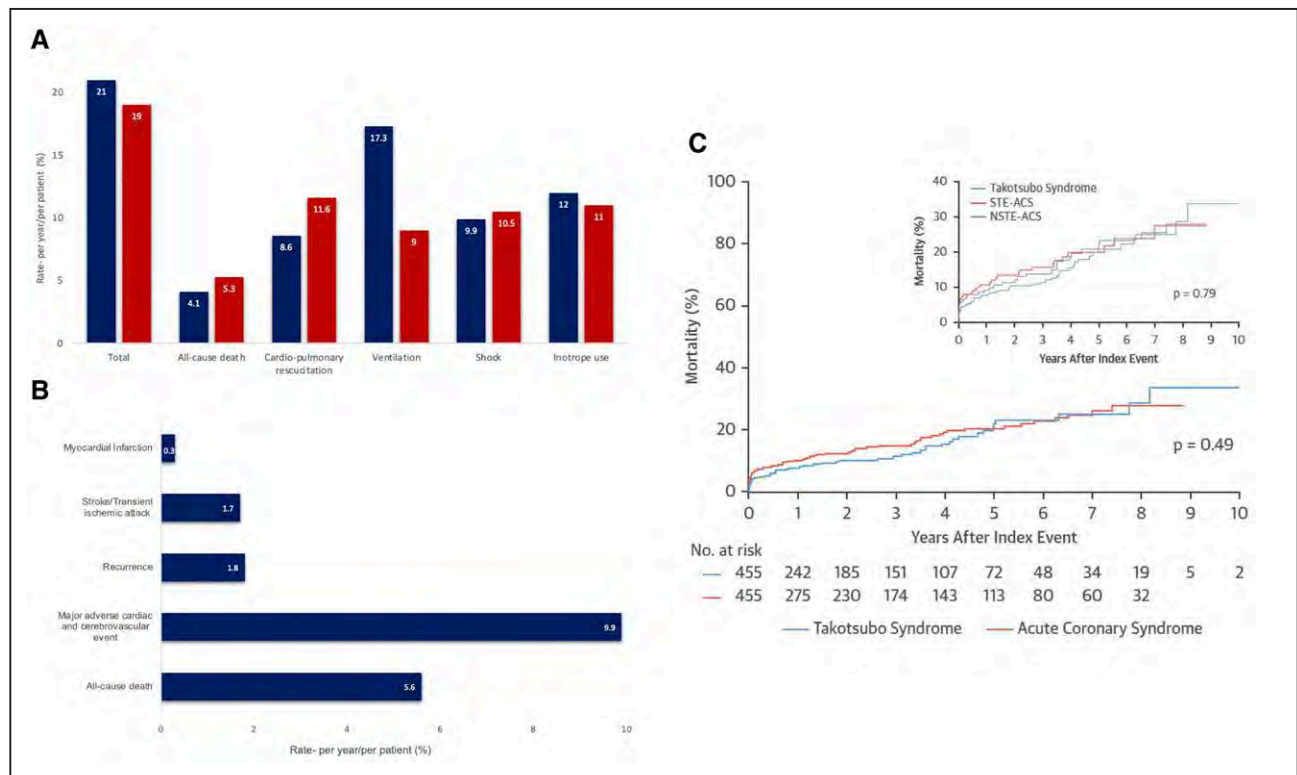


Figure 4. Outcomes in takotsubo syndrome.

A, In-hospital complications in patients with takotsubo syndrome (blue) and patients with acute coronary syndrome (red). **B**, Long-term outcomes in patients with takotsubo cardiomyopathy. **C**, Kaplan-Meier curves for long-term mortality in patients with takotsubo syndrome compared with patients with acute coronary syndrome. Reprinted from Ghadri et al¹⁵ with permission. Copyright © 2018, the Authors. NSTEMI-ACS indicates non-ST-segment-elevation acute coronary syndrome; and STE-ACS, ST-segment-elevation acute coronary syndrome.

aggravate systolic dysfunction because excess catecholamines may be involved in the underlying pathogenesis and pathophysiology of the condition. As such, expert consensus recommends mechanical approaches to provide hemodynamic support, such as intra-aortic balloon counterpulsation, temporary left ventricular assist devices, and extracorporeal membrane oxygenation.^{25,63} However, identification of left ventricular outflow obstruction is important because hemodynamic status may be worsened by intra-aortic balloon counterpulsation in such cases. When mechanical support is not available, low-dose levosimendan is licensed in some countries as a catecholamine-sparing positive inotrope (Table 2).^{65,66}

Arrhythmias

The management of ventricular arrhythmias depends on the clinical picture and mirrors the general principles of acute arrhythmia management. It is important to avoid QT segment-prolonging medications because these may worsen the likelihood of developing ventricular arrhythmias because of the high risk of further QTc prolongation. In clinical practice, electric pacing of torsade de pointes has proven successful to bridge the patient and allow recovery from the acute phase. Although uncommon, if high-degree atrioventricular block is present, inotropes and permanent devices should be avoided, semipermanent

(active fixation lead connected to an externalized pulse generator) or temporary right ventricular pacing may be considered if there is hemodynamic instability.^{25,67} Patients who present with life-threatening ventricular arrhythmias and takotsubo syndrome should be considered for an implantable cardiac defibrillator. However, there is no specific evidence base to support this approach and there are no long-term outcome data of device discharge rates in patients with takotsubo syndrome.²⁵

Thromboembolism

Patients who have a confirmed left ventricular thrombus should be treated with anticoagulants for at least 3 months or until resolution. Although no guidelines currently exist for the treatment of takotsubo syndrome, the relatively high rates of systemic thromboembolism would suggest that better identification of thrombus on cardiac imaging is needed before discharge and should be considered in high-risk patients, such as those with severe left ventricular dysfunction (ejection fraction <30%) and apical ballooning.

LONG-TERM MANAGEMENT

As with in-hospital management, no therapeutic interventions have been shown to reduce recurrences or any other major cardiovascular events in patients with takotsubo

Table 2. Management Pathway in Patients With Takotsubo Syndrome

Management	
Acute complications	
Heart failure/pulmonary edema	Diuretics, nitroglycerin (if no left ventricular outflow obstruction)
Left ventricular outflow obstruction	Consider: intravenous fluids, β -blocker (if no heart failure), left ventricular assist device Avoid: diuretics, nitroglycerin, intra-aortic balloon pump
Shock/pump failure	Consider: left ventricular assist device, venous to arterial extracorporeal membrane oxygenation Avoid: inotropes such as epinephrine, norepinephrine, dobutamine, milrinone, and isoprenaline
Arrhythmias	Ventricular arrhythmias: β -blocker, magnesium, direct current cardioversion Avoid: QT prolonging drugs High-degree atrioventricular block: temporary pacing Avoid: β -blockers, permanent devices
Thromboembolism	Left ventricular thrombus: Anticoagulation for at least 3 mo Consider: Prophylactic anticoagulation in patients with left ventricular ejection fraction <30% and apical ballooning
PredischARGE	
Bystander coronary disease	Secondary prevention: antiplatelet and statin therapy
Left ventricular dysfunction	Heart failure treatment: β -blockers, angiotensin-converting enzyme inhibitors or angiotensin receptor blockers, diuretics
Tachycardia	β -Blocker, ivabradine (if in sinus and cannot tolerate β -blockers)
Assess for left ventricular thrombus	Cardiac imaging and assessment for anticoagulation
Long term	
Recurrence prevention	Treat cardiovascular risk factors
Address risk factors	Underlying mental health conditions

syndrome. The focus is therefore to ensure the treatment of associated risk factors and concomitant disease.

Concomitant Disease

Patients with concomitant coronary artery disease (bystander disease) should continue to receive preventative therapies including antiplatelet, statin, and angiotensin-converting enzyme inhibitor therapies. Furthermore, those who have dual pathology (concurrent acute myocardial infarction) may require dual antiplatelet therapy, and treatment should be tailored to individual patients (Daghem et al, A tear and a broken heart. 2022). Where patients demonstrate a degree of persistent left ventricular systolic dysfunction, they should be managed and treated for left ventricular systolic dysfunction according to established guidelines.⁶³ However, in the vast majority of patients who have normalization of their left ventricular ejection fraction, there is no clear evidence that β -blocker therapy improves long-term survival benefit or reduces the recurrence of takotsubo syndrome.^{9,65,68} Likewise, the evidence for angiotensin-converting enzyme inhibitor or angiotensin receptor blocker therapy is contradictory and uncertain.^{9,65,69} Randomized controlled trial evidence is urgently needed. In the meantime, each clinician should continue to apply their best judgment, but conservative medical management appears to be the most appropriate approach in the absence of treatable risk factors or comorbidities.

Risk Factors

Psychiatric disorders, usually anxiety or depression, are common in patients with takotsubo syndrome, suggesting that some patients might benefit from a combined psychocardiological rehabilitation. Cognitive-behavioral therapy alongside cardiac rehabilitation can improve mental health and reduce negative thinking compared with cardiac rehabilitation alone.⁷⁰ Studies are currently underway to establish whether structured exercise training and mental well-being programs can improve cardiac energetics and attenuate cardiac limitation on exercise after takotsubo syndrome (PLEASE study [Physical Exercise and Mental Wellbeing Rehabilitation for Acute Stress-induced Takotsubo Cardiomyopathy: The PLEASE Study]; NCT04425785). Whether antidepressant or other psychiatric therapies might provide clinical benefit in such patients is controversial and has not been investigated.

PATHOGENESIS AND PATHOPHYSIOLOGY

Understanding the underlying pathogenesis and pathophysiology (Figure 5) is critical if appropriate treatments are to be developed for the acute episode, and the prevention of subsequent long-term recurrent events, as well. Furthermore, it is unknown whether the underlying mechanism varies according to the anatomic variation of the left myocardial ballooning.

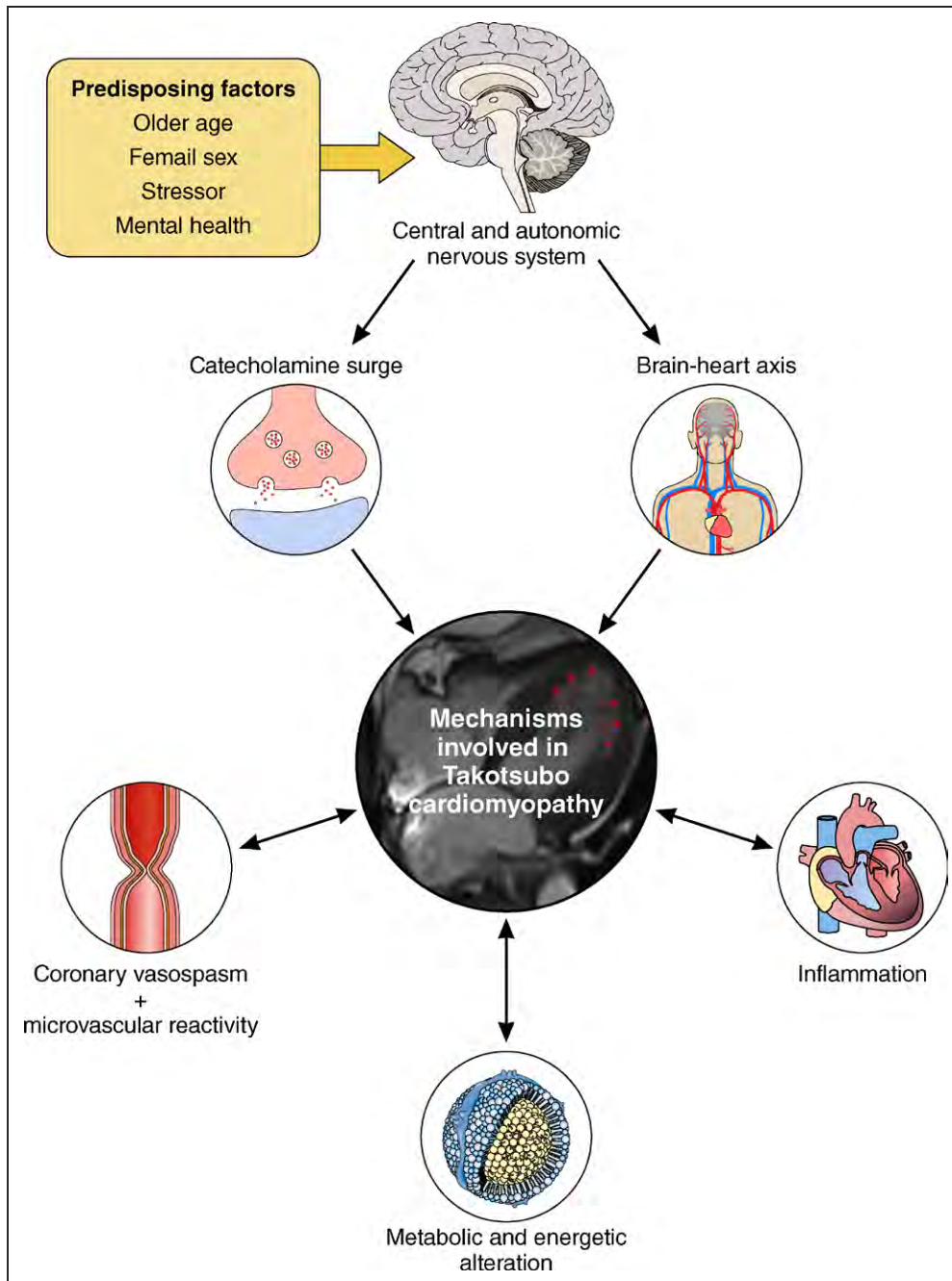


Figure 5. Mechanisms involved in takotsubo syndrome.

Adrenergic Hypothesis

Endogenous adrenergic surge is the most established theory for the pathogenesis of takotsubo syndrome and is intuitive given the strong association with sudden unexpected stress and major physical illness or trauma.

Two principal aspects to this mechanism need to be considered: the release of catecholamines and the cardiac response to catecholamines. The locus coeruleus, located in the posterior part of the rostral pons, is the primary origin of norepinephrine in the brain. Receiving multiple inputs from the limbic system, it regulates the homeostatic response to emotions.⁷¹ The locus coeruleus

is triggered by emotional stimuli and leads to the production of norepinephrine, which in turn activates the hypothalamic-pituitary-adrenal axis.⁷¹ In response to this activation, the adrenal medulla releases epinephrine and norepinephrine into the circulation, thereby increasing plasma catecholamine concentrations.

Iga and colleagues⁷² were the first to describe takotsubo syndrome in a patient with pheochromocytoma. This particular case report was important because it first established the relationship between takotsubo syndrome and elevated catecholamine concentrations. Subsequent observational studies have demonstrated

elevated blood catecholamine concentrations in the acute phase, although this has not been a universal finding.⁷³ Preclinical studies have shown that intravenous or intraperitoneal administration of norepinephrine, epinephrine, or isoprenaline can reproduce the characteristic reversible apical left ventricular ballooning coupled with basal hypercontractility.^{74,75}

Independent of a systemic increase in catecholamine concentrations through the hypothalamic-pituitary-adrenal axis, a local neurally mediated increase in catecholamine release at myocardial level may also occur.⁷⁶ Apart from the locus coeruleus, neural impulses descend (from the rostral pons) into posterior hypothalamus triggering norepinephrine release from sympathetic nerve terminals supplying the myocardium and coronary circulation. Increase in local production may explain why plasma catecholamine concentrations are not always elevated, and several studies have demonstrated myocardial sympathetic hyperactivity.

The second aspect is the cardiovascular response to a surge in catecholamines and how this results in left ventricular dysfunction. Mammalian hearts demonstrate the highest density of β -adrenergic receptors in the apex, although the distribution of β_1 - and β_2 -adrenoreceptors has never been mapped in the human heart.²³ Increased responsiveness of the left ventricular apex to catecholamines could explain the characteristic apical ballooning of takotsubo syndrome.⁷⁷

Some have suggested direct myocardial injury from catecholamine excess. Furthermore, catecholamines released directly into the myocardium through sympathetic nerves may have a greater toxic effect than that reaching the heart through the bloodstream.⁷⁷ Norepinephrine spillover can decrease myocyte viability, resulting in contraction band necrosis, which is one of the histological findings reported in takotsubo syndrome (Figure 2).^{78,79} Contraction band necrosis is also found in patients with pheochromocytoma and subarachnoid

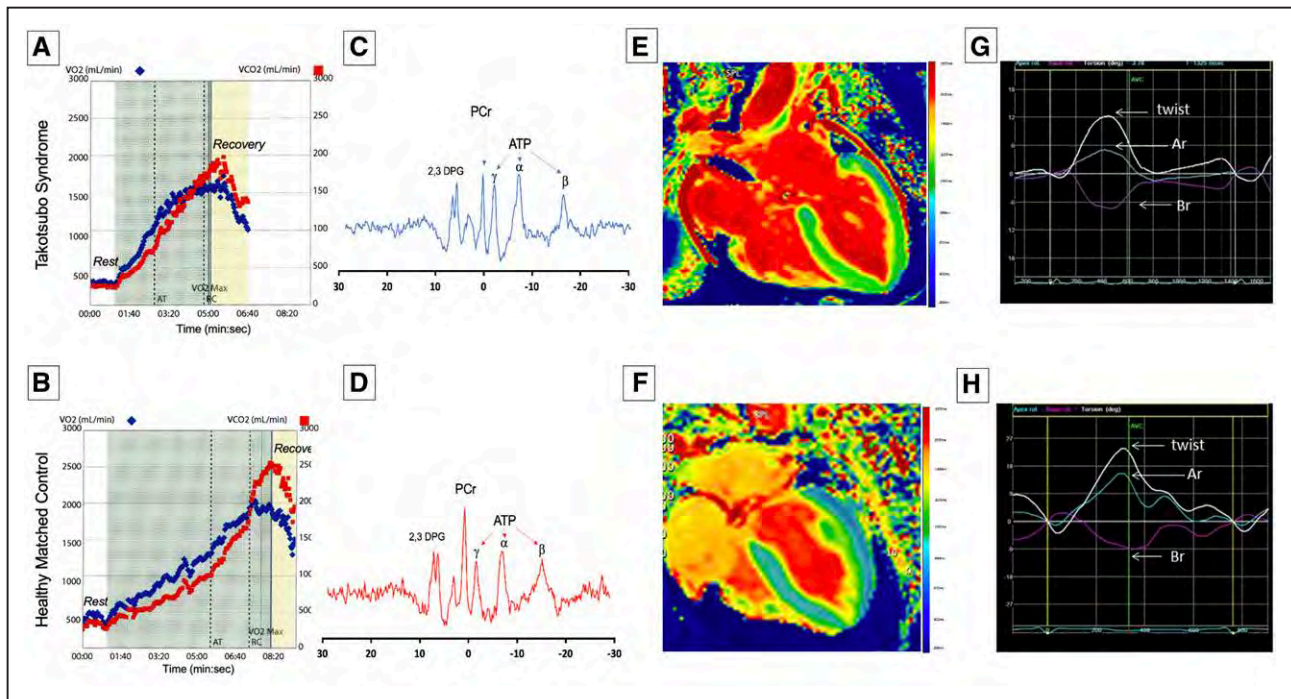


Figure 6. Abnormal exercise capacity, energetics, and cardiac performance in patients with takotsubo syndrome.

Cardiopulmonary exercise (treadmill) data from a patient with previous takotsubo syndrome 20 months earlier (A) and an age- and sex-matched healthy control subject (B). The maximal oxygen consumption (V_{O_2} , blue dots) achieved by the patient with takotsubo syndrome is markedly reduced, with an earlier anaerobic threshold and a shorter duration of exercise than the healthy control subject. ³¹P phosphorus magnetic resonance spectroscopy acquisition for a patient with acute takotsubo syndrome (C) and healthy volunteer (D) showing reduced phosphocreatine/adenosine triphosphate ratio. Resonances correspond to phosphocreatine (PCr), γ , β , and α adenosine triphosphate (ATP), and 2,3-diphosphoglycerate (2,3 DPG). Manganese-enhanced magnetic resonance imaging in a patient with acute takotsubo syndrome (E) and an age- and sex-matched volunteer (F). The patient demonstrates abnormal calcium activity (green) throughout the mid ventricle and apex with preserved calcium activity in the basal segments (blue). In comparison, the healthy control subject demonstrates normal calcium activity throughout the myocardium (blue). Twist curves in a patient with takotsubo syndrome at 2-year follow-up (G) and an age- and sex-matched healthy control volunteer (H). The healthy subject demonstrates the characteristic early systolic twist in a clockwise rotation at the apex (blue trace) and in counterclockwise rotation at the base (purple trace), occurring during isovolumic contraction. This is followed by counterclockwise apical rotation (Ar; blue) and clockwise basal rotation (Br; purple), which results in the net systolic twist during left ventricular ejection (twist, white line). In comparison, the patient with takotsubo syndrome demonstrates incomplete recovery of left ventricular twist, predominantly because of the reduced apical rotation. AT indicates anaerobic threshold; V_{CO_2} (mL/min), volume of carbon dioxide exhaled; V_{O_2} (mL/min), volume of oxygen inspired; and V_{O_2} Max, maximal volume of oxygen inspired.

hemorrhage, which have also been attributed to catecholamine excess.^{78,79}

Some authors have hypothesized that a surge in adrenoceptor stimulation dysregulates myocardial calcium handling. Immunohistochemistry studies suggest that calcium-regulating proteins such as phospholamban, sarcoendoplasmic reticulum calcium-ATPase, and sarcolipin are altered, resulting in depressed left ventricular contraction during acute takotsubo syndrome.⁸⁰ Studies are presently underway that aim to assess myocardial calcium handling in patients with takotsubo syndrome (MEMORY study [Manganese-Enhanced Magnetic Resonance Imaging {MEMRI} in Ischaemic, Inflammatory and Takotsubo Cardiomyopathy], NCT04623788; Figure 6). Others have suggested that adrenoceptor stimulation can create an imbalance of oxygen supply and demand, thus creating myocellular hypoxia. Hypoxia is further exacerbated by metabolic changes and electrolyte imbalances from alterations in membrane permeability that may contribute to myocardial toxicity.

At high concentrations, epinephrine can act as a negative inotrope through ligand-mediated stimulatory Gs protein. After cAMP-dependent phosphorylation of the β_2 -adrenoceptor, receptor coupling is switched from the Gs to Gi protein.⁷⁵ The Gi protein prevents excessive activation of the myocyte and reduces contractility, which protects the myocardium from the effects of excess catecholamine stimulation and restricts cardiac damage.⁷⁵ The switch back to Gs protein is responsible for the rapid recovery in these patients and could explain resolution of left ventricular dysfunction. However, this theory does not explain all the features of takotsubo syndrome, such as the presence of marked myocardial edema, absence of a stressor in some patients, and why only two-thirds of patients have elevated catecholamine concentrations.

In the final analysis, it should be remembered that patients with takotsubo syndrome are neither tachycardic nor hypertensive at presentation, and this contrasts with all other conditions known to have high catecholamine surges. Thus, takotsubo syndrome might affect the autonomic nervous system in a much more complex way than a simple and pure catecholamine surge.

Brain–Heart Axis

For many patients, psychological stress is the central trigger for takotsubo syndrome, even in the presence of a physical illness, which arguably induces an element of psychological stress. Patients with takotsubo syndrome are more likely to have preexisting psychiatric illness. Patients with depression and anxiety have upregulated microRNA 16 and 26a, and in a rodent model of microRNA 16 and microRNA 26a overexpression, exogenous epinephrine was associated with apical wall motion abnormalities.^{81,82} This mechanism is consistent with a predilection of the myocardium to develop takotsubo syndrome in response to stress and could explain the high

prevalence of preexisting and acute psychiatric illness in affected individuals.

Neurocardiogenic stunning of the heart is a well-recognized complication after acute neurological injury, and 20% to 30% of patients develop transient left ventricular systolic dysfunction, highlighting the complex brain–heart interaction.⁸³ Patients with takotsubo syndrome demonstrate altered neuronal connectivity in several stress-associated limbic regions. Altered neuronal activity is predominately seen in the hippocampus, amygdala, cingulate gyrus, and insula and is important in regulating emotional responses and the autonomic nervous system.⁸⁴ Furthermore, 18F-fluorodeoxyglucose positron emission tomography imaging has demonstrated heightened amygdala activity years before patients develop takotsubo syndrome.⁸⁴ This suggests that, when presented with a potential trigger, such individuals may have a weakened ability to respond appropriately, and an imbalance of the sympathetic and parasympathetic nervous systems results in myocardial injury similar to that of an acute neurological insult.⁸⁵

Several case reports have described takotsubo syndrome in patients after cardiac transplantation. Given denervation of the heart after cardiac transplantation, this does argue against a direct neural stimulus as the trigger for takotsubo syndrome and suggests that humoral mechanisms may have a more prominent role. It has been postulated that parasympathetic denervation may lead to upregulation of catecholamines and β -adrenoceptors.⁸⁶ Combined with impaired neural innervation, this may result in an exaggerated response to catecholamines and susceptibility to takotsubo syndrome. The brain–heart axis is yet to be properly explored and possibly holds the answers to a number of questions that elude us regarding takotsubo syndrome and possibly other cardiac diseases.

Coronary Vasospasm and Microvascular Reactivity

Initial cases from Japan demonstrated multivessel epicardial coronary vasospasm on coronary angiography, raising the possibility that multivessel vasospasm may be a causative factor in the pathogenesis of takotsubo syndrome.⁷⁷ However, repeated provocation testing in patients with takotsubo syndrome found such responses to be inconsistent with only \approx 20% of patients demonstrating reproducible vasospasm.⁸⁷ Furthermore, such provocation testing is not physiological, has poor reproducibility, and is of uncertain relevance to spontaneous epicardial spasm.

Microvascular dysfunction and impaired reactivity do appear to be a feature of takotsubo syndrome with demonstrable reversible abnormalities in both the coronary flow reserve and the index of microvascular resistance. Postmenopausal women have age-related and estrogen deficiency-related coronary vasomotor

dysfunction. Under physiological circumstances, estrogen improves coronary blood flow through endothelium-dependent and -independent mechanisms, but its deficiency results in increased sympathetic drive and endothelial dysfunction.⁸⁸ These changes may in part explain the preponderance of takotsubo syndrome occurrence in postmenopausal women.

Nuclear myocardial perfusion studies have reported reduced apical perfusion, which gradually recovers at 1 and 6 months.⁸⁹ Such microvascular dysfunction and abnormal perfusion may be driven by vasoconstrictor mediators such as endothelin, catecholamines, and the associated reactive oxygen species.⁹⁰ Another possible explanation may be myocardial inflammation leading to direct myocyte injury, including vascular endothelial injury causing shedding of the endothelial glycocalyx and consequent myocardial edema. However, there are issues of cause and effect for both myocardial edema and microvascular dysfunction that may be a consequence rather than a cause of the acute episode.

Wittstein⁹¹ postulated the interaction between sympathetic overactivity and microvascular dysfunction and its impact on clinical presentation in patients with takotsubo syndrome. High-risk individuals with elevated sympathetic tone and vasomotor dysfunction (postmenopausal status, depression, and treatment with serotonin reuptake inhibitors) may only require a mild stimulus to precipitate microvascular ischemia and subsequent myocardial stunning.⁹¹ Conversely, low-risk individuals with normal sympathetic and vasomotor tone will likely require a much larger catecholamine surge to precipitate acute takotsubo syndrome. This may explain why some patients present after seemingly mild triggers.

Metabolic and Energetic Alterations

Current data demonstrate metabolic and energetic impairment in acute takotsubo syndrome followed by a protracted and incomplete recovery.⁴³ Preclinical studies have shown increased myocardial glucose uptake, and although there were appropriate increases in enzymes involved in the glycolytic pathway, there was a reduction in the available metabolites of glycolysis,⁹⁰ resulting in a decreased production of Krebs cycle intermediates. It is unknown whether this decrease is attributable to a state of myocardial metabolic enhancement leading to exhaustion and loss of metabolites or if this is attributable to myocardial metabolic stunning leading to enzymatic blockade of the glycolytic, β -oxidative, or pentose phosphate pathways.⁹⁰

The *in vivo* gold standard for exploring myocardial energetics is 31-phosphorus cardiac magnetic resonance spectroscopy. Resting cardiac energetic status (phosphocreatine to γ -ATP ratio) is reduced in patients with acute takotsubo syndrome (Figure 6). Although there is some recovery by 4 months of follow-up, it has still not completely normalized.⁹² Indeed, abnormal long-

term myocardial metabolism may explain why patients continue to be symptomatic and have recurrent events despite apparent recovery of left ventricular ejection fraction.⁵¹

Inflammatory Mechanisms

There is growing evidence to support the presence of myocardial inflammation in the acute phase of takotsubo syndrome. Although this will, in part, be a reaction to the precipitating event, it may be both cause and effect. Furthermore, a maladaptive persistent subacute or chronic inflammation may contribute to long-term cardiac dysfunction.

In a multicenter study (TERRIFIC [Pathogenesis of Acute Stress Induced {Tako-tsubo} Cardiomyopathy: Energy Shut-Down or Intense Inflammation?], NCT02897739),⁴³ patients with takotsubo syndrome had greater retention of ultrasmall superparamagnetic particles of iron oxide in both ballooning and nonballooning left ventricular segments during the acute phase. Because ultrasmall superparamagnetic particles of iron oxide are predominantly phagocytosed by activated tissue-resident macrophages, the main cellular protagonists of the myocardial cellular inflammation in acute takotsubo syndrome appear to be macrophages, whereas acute myocarditis is principally lymphocyte mediated. In addition, serum interleukin-6 and chemokine (C-X-C motif) ligand 1 concentrations, and classic CD14⁺⁺CD16 monocytes, as well, are increased, whereas intermediate CD14⁺⁺CD16⁺ and nonclassic monocytes are reduced in patients with takotsubo syndrome. At 5 months of follow-up, enhancement with ultrasmall superparamagnetic particles of iron oxide was no longer detectable in the myocardium, although persistent elevations in serum interleukin-6 concentrations and reductions in intermediate CD14⁺⁺CD16⁺ monocytes were present. Therefore, takotsubo syndrome is characterized by a myocardial macrophage inflammatory infiltrate, changes in the distribution of monocyte subsets, and an increase in systemic proinflammatory cytokines. Many of these changes persisted for at least 5 months, suggesting a low-grade chronic inflammatory state. Furthermore, postmortem examination of human hearts from patients who died during the acute phase of the condition demonstrated that these macrophages are predominantly of the M1 proinflammatory type as opposed to the reparative M2 type.⁹³ The presence of M1 macrophages and the persistence of the intermediate (CD14⁺⁺CD16⁺) monocyte subset at 5 months follow-up are strongly indicative of a less reparative and more proinflammatory state compared with similar stages of patients with acute myocardial infarction. It remains unclear, however, if this inflammatory activation is causative or consequential to takotsubo syndrome. Nevertheless, these findings offer an explanation for the low-grade chronic inflammatory substrate with subsequent evolution of acute takotsubo into long-term heart failure.

Persistent or Preexisting Syndrome

The heart failure phenotype of takotsubo syndrome has been thoroughly characterized in a cohort of predominantly symptomatic patients (the HEROIC study [Persistent Symptoms and Early Incomplete Recovery After Acute Stress-induced Cardiomyopathy: Is There Ongoing Heart Distress?], NCT02989454)⁵¹ and demonstrates preserved ejection fraction, impaired cardiac energetic status, cardiac limitation on exercise (reduced peak $\dot{V}O_2$ and increased $\dot{V}E/\dot{V}CO_2$ slope during cardiopulmonary exercise testing), reduced apical myocardial anticlockwise rotation during systole with altered torsion and twist, and possibly microscopic fibrosis (Figure 6).^{43,51} Likewise, cardiac biomarkers, such as BNP, remain mildly elevated long term.⁹⁴ This persistence of long-term myocardial abnormalities does beg the question of whether such abnormalities predate the index takotsubo syndrome. This would be consistent with the predisposition for recurrent takotsubo events. Of course, it is difficult to know whether the myocardium in these patients was healthy to begin with or there was a preexisting subtle and undiagnosed cardiomyopathy that is brought to light during an acute stressful event. If this were the case, then it would imply that their cardiac function may never return to normal and has in fact returned to baseline.

FUTURE DIRECTIONS

With advances in imaging, patients being examined for takotsubo syndrome should undergo multimodal noninvasive imaging. Not only does this increase the accuracy of the diagnosis, but it also allows for risk stratification and prognostication. The precise diagnosis of takotsubo syndrome does rely on the combination of clinical context, echocardiography, cardiac catheterization, and cardiac magnetic resonance imaging. Future exploration of a single sensitive and specific diagnostic test would greatly simplify clinical care pathways and would give added impetus to future therapeutic trials by identifying a more homogeneous patient population.

There is a major lack of evidence to guide management in patients with takotsubo syndrome, and this needs to be the focus of future research. Two main therapeutic domains need addressing. First, the management of acute takotsubo syndrome needs to be defined, especially guidance on the treatment of severe complications, such as cardiogenic shock. Second, the prevention of recurrent major adverse cardiac and cerebrovascular events is crucial. This includes the role of heart failure therapies to prevent reoccurrence of takotsubo syndrome, anticoagulant therapies to prevent ischemic strokes and psychiatric interventions, specifically in those with underlying mental health problems. Randomized controlled trials such as NACRAM (*N*-Acetylcysteine and Ramipril Takotsubo Syndrome Trial,

ACTRN12616000781448)⁹⁵ and BROKEN-SWEDEHEART (Optimized Pharmacological Treatment for Broken Heart [Takotsubo] Syndrome, NCT04666454) are currently assessing potential interventions and will be invaluable in informing treatment guidelines.

Given the presence of substantial and protracted myocardial inflammation, a potential role for anti-inflammatory therapies may have a role in the recovery from takotsubo syndrome. Long-term cardiac energetic impairment may also be 1 reason why patients continue to have symptoms and are prone to recurrent episodes despite apparent recovery of left ventricular ejection fraction. Interventions targeting these impairments of cardiac metabolism could be beneficial. For example, the benefits of sodium-glucose transporter 2 inhibitor therapy in heart failure may be related to an improvement in cardiac efficiency because of a shift in cardiac metabolism and could potentially be applicable to the takotsubo syndrome.^{96,97} Further studies of specific substrate use and enhancement of cardiomyocyte metabolic pathways are an attractive investigative pathway.

Patients with takotsubo syndrome have persistent symptomatic and functional impairment, and recurrent major events, as well, and it is essential that future studies focus on the long-term assessment of cardiac function, metabolism, symptoms, and clinical outcomes. This will be the focus of the Inter-TAK registry (International Takotsubo Registry, NCT01947621),^{11,47} which has launched a 10-year follow-up study in patients with takotsubo syndrome. This will also help identify different subtypes of takotsubo syndrome that may require distinct cause-specific interventions.

CONCLUSIONS

Takotsubo syndrome is increasing in incidence and becoming more widely recognized in the medical community. The diagnosis can be challenging, and clinicians must look for signs distinguishing takotsubo syndrome from other causes of acute myocardial injury. The use of multimodality imaging may help in this regard and improve our understanding of its underlying pathogenesis and pathophysiology. At present, takotsubo syndrome remains a poorly understood condition with substantial morbidity and mortality without proven or effective treatments that urgently need to be addressed.

ARTICLE INFORMATION

Affiliations

British Heart Foundation Centre for Cardiovascular Science, University of Edinburgh, United Kingdom (T.S., C.S., D.E.N.). Aberdeen Cardiovascular and Diabetes Centre, University of Aberdeen, United Kingdom (H.K., D.T.G., D.D.).

Sources of Funding

Dr Singh is supported by the British Heart Foundation (RE/18/5/34216) and Medical Research Council (MR/T-29/53/1). Dr Newby is supported by the Brit-

ish Heart Foundation (CH/09/002, RG/16/10/32375, RE/18/5/34216) and is the recipient of a Wellcome Trust Senior Investigator Award (WT103782AIA). Dr Gamble is supported by the British Heart Foundation (PG/18/35/33786). Dr Dawson is supported by the British Heart Foundation (FS/RTF/20/30009, NH/19/1/34595, PG/18/35/33786, CS/17/4/32960, PG/15/88/31780, PG/17/64/33205), Chest Heart and Stroke Scotland (19/53), Tenovus Scotland (G.18.01), Friends of Anchor and Grampian NHS-Endowments.

Disclosures

None.

REFERENCES

- Sato TH, Uchida T, Dote KMI. Tako-tsubo-like left ventricular dysfunction due to multivessel coronary spasm. In: Kodama K, Haze K, Hori M, eds. *Clinical Aspect of Myocardial Injury: From Ischemia to Heart Failure*. Tokyo, Japan: Kagakuhyoronsha Publishing Co; 1990:56–64.
- Engel GL. Sudden and rapid death during psychological stress. Folklore or folk wisdom? *Ann Intern Med*. 1971;74:771–782. doi: 10.7326/0003-4819-74-5-771
- Rees WD, Lutkins SG. Mortality of bereavement. *BMJ*. 1967;4:13–16. doi: 10.1136/bmj.4.5570.13
- Minhas AS, Hughey AB, Kolia TJ. Nationwide trends in reported incidence of takotsubo cardiomyopathy from 2006 to 2012. *Am J Cardiol*. 2015;116:1128–1131. doi: 10.1016/j.amjcard.2015.06.042
- Pattisapu VK, Hao H, Liu Y, Nguyen TT, Hoang A, Bairey Merz CN, Cheng S. Sex- and age-based temporal trends in takotsubo syndrome incidence in the United States. *J Am Heart Assoc*. 2021;10:e019583. doi: 10.1161/JAHA.120.019583
- Kurusu S, Sato H, Kawagoe T, Ishihara M, Shimatani Y, Nishioka K, Kono Y, Umemura T, Nakamura S. Tako-tsubo-like left ventricular dysfunction with ST-segment elevation: a novel cardiac syndrome mimicking acute myocardial infarction. *Am Heart J*. 2002;143:448–455. doi: 10.1067/mhj.2002.120403
- Tsuchihashi K, Ueshima K, Uchida T, Oh-mura N, Kimura K, Owa M, Yoshiyama M, Miyazaki S, Haze K, Ogawa H, et al. Transient left ventricular apical ballooning without coronary artery stenosis: a novel heart syndrome mimicking acute myocardial infarction. Angina pectoris-myocardial infarction investigations in Japan. *J Am Coll Cardiol*. 2001;38:11–18. doi: 10.1016/s0735-1097(01)01316-x
- Tornvall P, Collste O, Ehrenborg E, Jämbert-Pettersson H. A case-control study of risk markers and mortality in takotsubo stress cardiomyopathy. *J Am Coll Cardiol*. 2016;67:1931–1936. doi: 10.1016/j.jacc.2016.02.029
- Templin C, Ghadri JR, Diekmann J, Napp LC, Bataiosu DR, Jaguszewski M, Cammann VL, Sarcon A, Geyer V, Neumann CA, et al. Clinical features and outcomes of takotsubo (stress) cardiomyopathy. *N Engl J Med*. 2015;373:929–938. doi: 10.1056/NEJMoa1406761
- Uribarri A, Núñez-Gil IJ, Conty DA, Vedia O, Almendro-Delia M, Duran Cambra A, Martín-García AC, Barrionuevo-Sánchez M, Martínez-Sellés M, Raposeiras-Roubin S, et al. Short- and long-term prognosis of patients with takotsubo syndrome based on different triggers: importance of the physical nature. *J Am Heart Assoc*. 2019;8:e013701. doi: 10.1161/JAHA.119.013701
- Ghadri JR, Kato K, Cammann VL, Gili S, Jurisic S, Di Vece D, Candreva A, Ding KJ, Micek J, Szawan KA, et al. Long-term prognosis of patients with takotsubo syndrome. *J Am Coll Cardiol*. 2018;72:874–882. doi: 10.1016/j.jacc.2018.06.016
- Brinjikji W, El-Sayed AM, Salka S. In-hospital mortality among patients with takotsubo cardiomyopathy: a study of the National Inpatient Sample 2008 to 2009. *Am Heart J*. 2012;164:215–221. doi: 10.1016/j.ahj.2012.04.010
- Redfors B, Jha S, Thorleifsson S, Jernberg T, Angerås O, Frobert O, Petrusson P, Tornvall P, Sarno G, Ekenbäck C, et al. Short- and long-term clinical outcomes for patients with takotsubo syndrome and patients with myocardial infarction: a report from the Swedish Coronary Angiography and Angioplasty Registry. *J Am Heart Assoc*. 2021;10:e017290. doi: 10.1161/JAHA.119.017290
- Akashi YJ, Goldstein DS, Barbaro G, Ueyama T. Takotsubo cardiomyopathy: a new form of acute, reversible heart failure. *Circulation*. 2008;118:2754–2762. doi: 10.1161/CIRCULATIONAHA.108.767012
- Ghadri JR, Wittstein IS, Prasad A, Sharkey S, Dote K, Akashi YJ, Cammann VL, Crea F, Galiuto L, Desmet W, et al. International expert consensus document on takotsubo syndrome (part I): clinical characteristics, diagnostic criteria, and pathophysiology. *Eur Heart J*. 2018;39:2032–2046. doi: 10.1093/eurheartj/ehy076
- Napp LC, Cammann VL, Jaguszewski M, Szawan KA, Wischnewsky M, Gili S, Knorr M, Heiner S, Citro R, Bossone E, et al. Coexistence and outcome of coronary artery disease in Takotsubo syndrome. *Eur Heart J*. 2020;41:3255–3268. doi: 10.1093/eurheartj/ehaa210
- Cammann VL, Szawan KA, Stähli BE, Kato K, Budnik M, Wischnewsky M, Dreiding S, Levinson RA, Di Vece D, Gili S, et al. Age-related variations in takotsubo syndrome. *J Am Coll Cardiol*. 2020;75:1869–1877. doi: 10.1016/j.jacc.2020.02.057
- Matsukawa T, Sugiyama Y, Watanabe T, Kobayashi F, Mano T. Gender difference in age-related changes in muscle sympathetic nerve activity in healthy subjects. *Am J Physiol*. 1998;275:R1600–R1604. doi: 10.1152/ajpregu.1998.275.5.R1600
- Parashar R, Amir M, Pakhare A, Rathi P, Chaudhary L. Age related changes in autonomic functions. *J Clin Diagn Res*. 2016;10:CC11–CC15. doi: 10.7860/JCDR/2016/16889.7497
- Pelliccia F, Kaski JC, Crea F, Camici PG. Pathophysiology of takotsubo syndrome. *Circulation*. 2017;135:2426–2441. doi: 10.1161/CIRCULATIONAHA.116.027121
- Caretta G, Robba D, Vizzardi E, Bonadei I, Raddino R, Metra M. Tako-tsubo cardiomyopathy in two sisters: a chance finding or familial predisposition? *Clin Res Cardiol*. 2015;104:614–616. doi: 10.1007/s00392-015-0837-0
- Goodloe AH, Evans JM, Middha S, Prasad A, Olson TM. Characterizing genetic variation of adrenergic signalling pathways in Takotsubo (stress) cardiomyopathy exomes. *Eur J Heart Fail*. 2014;16:942–949. doi: 10.1002/ejhf.145
- Friz O, Minisini R, Citro R, Guerra V, Zito C, De Luca G, Pavan D, Pirisi M, Limongelli G, Bossone E. Analysis of beta1 and beta2-adrenergic receptors polymorphism in patients with apical ballooning cardiomyopathy. *Acta Cardiol*. 2011;66:787–790. doi: 10.1080/ac.66.6.2136964
- El-Batrawy I, Santoro F, Stiermaier T, Möller C, Guastafierro F, Novo G, Novo S, Mariano E, Romeo F, Romeo F, et al. Incidence and clinical impact of recurrent takotsubo syndrome: results from the GEIST Registry. *J Am Heart Assoc*. 2019;8:e010753. doi: 10.1161/JAHA.118.010753
- Ghadri JR, Wittstein IS, Prasad A, Sharkey S, Dote K, Akashi YJ, Cammann VL, Crea F, Galiuto L, Desmet W, et al. International expert consensus document on takotsubo syndrome (part II): diagnostic work-up, outcome, and management. *Eur Heart J*. 2018;39:2047–2062. doi: 10.1093/eurheartj/ehy077
- Lacey CJ, Doudney K, Bridgman PG, George PM, Mulder RT, Zarifeh JJ, Kimber B, Cadzow MJ, Black MA, Merriman TR, et al. Copy number variants implicate cardiac function and development pathways in earthquake-induced stress cardiomyopathy. *Sci Rep*. 2018;8:7548. doi: 10.1038/s41598-018-25827-5
- Jabri A, Kalra A, Kumar A, Alameh A, Adroja S, Bashir H, Nowacki AS, Shah R, Khubber S, Kanaa NA, et al. Incidence of stress cardiomyopathy during the coronavirus disease 2019 pandemic. *JAMA Netw Open*. 2020;3:e2014780. doi: 10.1001/jamanetworkopen.2020.14780
- Muratsu A, Muroya T, Kuwagata Y. Takotsubo cardiomyopathy in the intensive care unit. *Acute Med Surg*. 2019;6:152–157. doi: 10.1002/ams2.396
- Nagpal RR, Dhabhar JB, Ghanekar J. Takotsubo cardiomyopathy in a case of intracerebral hemorrhage: a case report. *Cureus*. 2019;11:e5711. doi: 10.7759/cureus.5711
- Patel V, Levy S, Malik I, Fertleman MB, Koizia LJ. Takotsubo cardiomyopathy in elderly female trauma patients: a case series. *J Med Case Rep*. 2021;15:451. doi: 10.1186/s13256-021-03056-1
- Vieira AC, Ribeiro MFSA, Lima J, Filho JS, de Andrade Carvalho H, Mano MS. Takotsubo syndrome induced by brachytherapy in a patient with endocervical adenocarcinoma. *Cardiooncology*. 2020;6:30. doi: 10.1186/s40959-020-00082-8
- Ghadri JR, Cammann VL, Napp LC, Jurisic S, Diekmann J, Bataiosu DR, Seifert B, Jaguszewski M, Sarcon A, Neumann CA, et al. Differences in the clinical profile and outcomes of typical and atypical takotsubo syndrome: data from the International Takotsubo Registry. *JAMA Cardiol*. 2016;1:335–340. doi: 10.1001/jamacardio.2016.0225
- Compare A, Bigi R, Orrego PS, Proietti R, Grossi E, Steptoe A. Type D personality is associated with the development of stress cardiomyopathy following emotional triggers. *Ann Behav Med*. 2013;45:299–307. doi: 10.1007/s12160-013-9474-x
- Singh T, Chapman AR, Dweck MR, Mills NL, Newby DE. MINOCA: a heterogeneous group of conditions associated with myocardial damage. *Heart*. 2021;107:1458–1464. doi: 10.1136/heartjnl-2020-318269

35. Namgung J. Electrocardiographic findings in takotsubo cardiomyopathy: ECG evolution and its difference from the ECG of acute coronary syndrome. *Clin Med Insights Cardiol*. 2014;8:29–34. doi: 10.4137/CMC.S14086
36. Frangieh AH, Obeid S, Ghadri JR, Imori Y, D'Ascenzo F, Kovac M, Ruschitzka F, Lüscher TF, Duru F, Templin C; InterTAK Collaborators. ECG criteria to differentiate between takotsubo (stress) cardiomyopathy and myocardial infarction. *J Am Heart Assoc*. 2016;5:e003418. doi: 10.1161/JAHA.116.003418
37. Scally C, Choo W, Rudd A, Neil C, Siddiqi N, Mezincescu AM, Wilson HM, Frenneaux M, Horgan G, Broadhurst P, et al. The early dynamic of ECG in Takotsubo syndrome presenting with ST-elevation: a comparison with age and gender-matched ST-elevation myocardial infarction. *Int J Cardiol*. 2020;320:7–11. doi: 10.1016/j.ijcard.2020.07.025
38. Choi SH, Lee O-H, Yoon G-S, Kwon SW, Shin S-H, Park S-D, Woo S-I, Kwan J, Kim D-H, Baek Y-S. The relationship between j wave and ventricular tachycardia during takotsubo cardiomyopathy. *Int J Arrhythm*. 2020;21. doi: 10.1186/s42444-020-00016-6
39. Budnik M, Kochanowski J, Piatkowski R, Wojtera K, Peller M, Gaska M, Glowacka P, Karolczak P, Ochjiewicz D, Opolski G. Simple markers can distinguish Takotsubo cardiomyopathy from ST segment elevation myocardial infarction. *Int J Cardiol*. 2016;219:417–420. doi: 10.1016/j.ijcard.2016.06.015
40. Hojagergaard MA, Hassager C, Christensen TE, Bang LE, Gøtzte JP, Ostrowski SR, Holmvang L, Frydland M. Biomarkers in patients with Takotsubo cardiomyopathy compared to patients with acute anterior ST-elevation myocardial infarction. *Biomarkers*. 2020;25:137–143. doi: 10.1080/1354750X.2019.1710767
41. Dagrenat C, Von Hunolstein JJ, Matsushita K, Thebaud L, Greciano S, Tuzin N, Meyer N, Trinh A, Jesel L, Ohlmann P, Morel O. Value of cardiac biomarkers in the early diagnosis of takotsubo syndrome. *J Clin Med*. 2020;9:E2985. doi: 10.3390/jcm9092985
42. Budnik M, Białek S, Peller M, Kiszczurno A, Kochanowski J, Kucharz J, Sitkiewicz D, Opolski G. Serum copeptin and copeptin/NT-proBNP ratio - new tools to differentiate takotsubo syndrome from acute myocardial infarction. *Folia Med Cracov*. 2020;60:5–14. doi: 10.24425/fmc.2020.133481
43. Scally C, Abbas H, Ahearn T, Srinivasan J, Mezincescu A, Rudd A, Spath N, Yucel-Finn A, Yucel R, Oldroyd K, et al. Myocardial and systemic inflammation in acute stress-induced (takotsubo) cardiomyopathy. *Circulation*. 2019;139:1581–1592. doi: 10.1161/CIRCULATIONAHA.118.037975
44. Santoro F, Costantino MD, Guastafierro F, Triggiani G, Ferraretti A, Tarantino N, Saguner A, Di Biase M, Brunetti ND. Inflammatory patterns in takotsubo cardiomyopathy and acute coronary syndrome: a propensity score matched analysis. *Atherosclerosis*. 2018;274:157–161. doi: 10.1016/j.atherosclerosis.2018.05.017
45. Gerbaud E, Arabucki F, Nivet H, Barbey C, Cetran L, Chassaing S, Seguy B, Lesimple A, Cochet H, Montaudon M, et al. OCT and CMR for the diagnosis of patients presenting with MINOCA and suspected epicardial causes. *JACC Cardiovasc Imaging*. 2020;13:2619–2631. doi: 10.1016/j.jcmg.2020.05.045
46. Arcari L, Musumeci MB, Stiermaier T, El-Battrawy I, Möller C, Guerra F, Novo G, Mariano E, Limite LR, Cacciotti L, et al. Incidence, determinants and prognostic relevance of dyspnea at admission in patients with Takotsubo syndrome: results from the international multicenter GEIST registry. *Sci Rep*. 2020;10:13603. doi: 10.1038/s41598-020-70445-9
47. Ghadri JR, Templin C. The InterTAK Registry for takotsubo syndrome. *Eur Heart J*. 2016;37:2806–2808. doi: 10.1093/eurheartj/ehw364
48. Liu K, Sun Z, Wei T. "Reverse McConnell's sign": interpreting interventricular hemodynamic dependency and guiding the management of acute heart failure during takotsubo cardiomyopathy. *Clin Med Insights Cardiol*. 2015;9(suppl 1):33–40. doi: 10.4137/CMC.S18756
49. Santoro F, Stiermaier T, Tarantino N, De Gennaro L, Moeller C, Guastafierro F, Marchetti MF, Montisci R, Carapelle E, Graf T, et al. Left ventricular thrombi in takotsubo syndrome: incidence, predictors, and management: results from the GEIST (German Italian Stress Cardiomyopathy) Registry. *J Am Heart Assoc*. 2017;6:e006990. doi: 10.1161/JAHA.117.006990
50. Lee M. Time course of functional recovery in takotsubo (stress) cardiomyopathy: a serial speckle tracking echocardiography and electrocardiography study. *J Cardiovasc Imaging*. 2020;28:50–60. doi: 10.4250/jcvi.2019.0083
51. Scally C, Rudd A, Mezincescu A, Wilson H, Srivanasan J, Horgan G, Broadhurst P, Newby DE, Henning A, Dawson DK. persistent long-term structural, functional, and metabolic changes after stress-induced (takotsubo) cardiomyopathy. *Circulation*. 2018;137:1039–1048. doi: 10.1161/CIRCULATIONAHA.117.031841
52. Agewall S, Beltrame JF, Reynolds HR, Niessner A, Rosano G, Caforio AL, De Caterina R, Zimarino M, Roffi M, Kjeldsen K, et al. ESC working group position paper on myocardial infarction with non-obstructive coronary arteries. *Eur Heart J*. 2017;38:143–153. doi: 10.1093/eurheartj/ehw149
53. Citro R, Okura H, Ghadri JR, Izumi C, Meimoun P, Izumo M, Dawson D, Kaji S, Eitel I, Kagiya N, et al. Multimodality imaging in takotsubo syndrome: a joint consensus document of the European Association of Cardiovascular Imaging (EACVI) and the Japanese Society of Echocardiography (JSE). *J Echocardiogr*. 2020;18:199–224. doi: 10.1007/s12574-020-00480-y
54. Abe Y, Kondo M, Matsuoka R, Araki M, Dohyama K, Tanio H. Assessment of clinical features in transient left ventricular apical ballooning. *J Am Coll Cardiol*. 2003;41:737–742. doi: 10.1016/s0735-1097(02)02925-x
55. Prasad A, Lerman A, Rihal CS. Apical ballooning syndrome (Tako-Tsubo or stress cardiomyopathy): a mimic of acute myocardial infarction. *Am Heart J*. 2008;155:408–417. doi: 10.1016/j.ahj.2007.11.008
56. Schultz T, Shao Y, Redfors B, Sverrisdóttir YB, Rámunddal T, Albertsson P, Matejka G, Omerovic E. Stress-induced cardiomyopathy in Sweden: evidence for different ethnic predisposition and altered cardio-circulatory status. *Cardiology*. 2012;122:180–186. doi: 10.1159/000338814
57. Wittstein IS. Stress cardiomyopathy: a syndrome of catecholamine-mediated myocardial stunning? *Cell Mol Neurobiol*. 2012;32:847–857. doi: 10.1007/s10571-012-9804-8
58. Parodi G, Citro R, Bellandi B, Provenza G, Marrani M, Bossone E; Tako-tsubo Italian Network (TIN). Revised clinical diagnostic criteria for Tako-tsubo syndrome: the Tako-tsubo Italian Network proposal. *Int J Cardiol*. 2014;172:282–283. doi: 10.1016/j.ijcard.2013.12.239
59. Maron BJ, Towbin JA, Thiene G, Antzelevitch C, Corrado D, Arnett D, Moss AJ, Seidman CE, Young JB; American Heart Association; Council on Clinical Cardiology, Heart Failure and Transplantation Committee; Quality of Care and Outcomes Research and Functional Genomics and Translational Biology Interdisciplinary Working Groups; Council on Epidemiology and Prevention. Contemporary definitions and classification of the cardiomyopathies: an American Heart Association Scientific Statement from the Council on Clinical Cardiology, Heart Failure and Transplantation Committee; Quality of Care and Outcomes Research and Functional Genomics and Translational Biology Interdisciplinary Working Groups; and Council on Epidemiology and Prevention. *Circulation*. 2006;113:1807–1816. doi: 10.1161/CIRCULATIONAHA.106.174287
60. Ghadri JR, Cammann VL, Jurisic S, Seifert B, Napp LC, Diekmann J, Bataiosu DR, D'Ascenzo F, Ding KJ, Sarcon A, et al. A novel clinical score (InterTAK Diagnostic Score) to differentiate takotsubo syndrome from acute coronary syndrome: results from the International Takotsubo Registry. *Eur J Heart Fail*. 2017;19:1036–1042. doi: 10.1002/ehfj.683
61. Di Vece D, Citro R, Cammann VL, Kato K, Gili S, Szawan KA, Micek J, Jurisic S, Ding KJ, Bacchi B, et al. Outcomes associated with cardiogenic shock in takotsubo syndrome. *Circulation*. 2019;139:413–415. doi: 10.1161/CIRCULATIONAHA.118.036164
62. Abanador-Kamper N, Kamper L, Wolfertz J, Vorpahl M, Haage P, Seyfarth M. Temporally increased stroke rate after Takotsubo syndrome: need for an anticoagulation? *BMC Cardiovasc Disord*. 2018;18:117. doi: 10.1186/s12872-018-0842-0
63. Lyon AR, Bossone E, Schneider B, Sechtem U, Citro R, Underwood SR, Sheppard MN, Figtree GA, Parodi G, Akashi YJ, et al. Current state of knowledge on Takotsubo syndrome: a position statement from the Taskforce on Takotsubo Syndrome of the Heart Failure Association of the European Society of Cardiology. *Eur J Heart Fail*. 2016;18:8–27. doi: 10.1002/ehfj.424
64. Madias JE. If channel blocker ivabradine vs. β -blockers for sinus tachycardia in patients with takotsubo syndrome. *Int J Cardiol*. 2016;223:877–878. doi: 10.1016/j.ijcard.2016.08.281
65. Santoro F, Ieva R, Musaico F, Ferraretti A, Triggiani G, Tarantino N, Di Biase M, Brunetti ND. Lack of efficacy of drug therapy in preventing takotsubo cardiomyopathy recurrence: a meta-analysis. *Clin Cardiol*. 2014;37:434–439. doi: 10.1002/clc.22280
66. Yaman M, Arslan U, Kaya A, Akyol A, Ozturk F, Okudan YE, Bayramoglu A, Bektas O. Levosimendan accelerates recovery in patients with takotsubo cardiomyopathy. *Cardiol J*. 2016;23:610–615. doi: 10.5603/CJ.a.2016.0100
67. Revilla-Martí P, Cueva-Recalde JF, Linares-Vicente JA, Río-Sánchez S, Ruiz-Arroyo JR. High-degree atrioventricular block. An unusual presentation of takotsubo cardiomyopathy: a case report. *Egypt Heart J*. 2021;73:18. doi: 10.1186/s43044-021-00144-x
68. Isogai T, Matsui H, Tanaka H, Fushimi K, Yasunaga H. Early β -blocker use and in-hospital mortality in patients with Takotsubo cardiomyopathy. *Heart*. 2016;102:1029–1035. doi: 10.1136/heartjnl-2015-308712

69. Singh K, Carson K, Shah R, Sawhney G, Singh B, Parsaik A, Gilutz H, Usmani Z, Horowitz J. Meta-analysis of clinical correlates of acute mortality in takotsubo cardiomyopathy. *Am J Cardiol*. 2014;113:1420–1428. doi: 10.1016/j.amjcard.2014.01.419
70. Wells A, Reeves D, Capobianco L, Heal C, Davies L, Heagerty A, Doherty P, Fisher P. Improving the effectiveness of psychological interventions for depression and anxiety in cardiac rehabilitation: PATHWAY—a single-blind, parallel, randomized, controlled trial of group metacognitive therapy. *Circulation*. 2021;144:23–33. doi: 10.1161/CIRCULATIONAHA.120.052428
71. Jakob MO, Murugan S, Klose CSN. Neuro-immune circuits regulate immune responses in tissues and organ homeostasis. *Front Immunol*. 2020;11:308. doi: 10.3389/fimmu.2020.00308
72. Iga K, Gen H, Tomonaga G, Matsumura T, Hori K. Reversible left ventricular wall motion impairment caused by pheochromocytoma—a case report. *Jpn Circ J*. 1989;53:813–818. doi: 10.1253/jcj.53.813
73. Wittstein IS, Thiemann DR, Lima JA, Baughman KL, Schulman SP, Gerstenblith G, Wu KC, Rade JJ, Bivalacqua TJ, Champion HC. Neurohumoral features of myocardial stunning due to sudden emotional stress. *N Engl J Med*. 2005;352:539–548. doi: 10.1056/NEJMoa043046
74. Heather LC, Catchpole AF, Stuckey DJ, Cole MA, Carr CA, Clarke K. Isoproterenol induces in vivo functional and metabolic abnormalities: similar to those found in the infarcted rat heart. *J Physiol Pharmacol*. 2009;60:31–39.
75. Paur H, Wright PT, Sikkal MB, Tranter MH, Mansfield C, O'Gara P, Stuckey DJ, Nikolae V, Diakonov I, Pannell L, et al. High levels of circulating epinephrine trigger apical cardiodepression in a β_2 -adrenergic receptor/Gi-dependent manner: a new model of Takotsubo cardiomyopathy. *Circulation*. 2012;126:697–706. doi: 10.1161/CIRCULATIONAHA.112.111591
76. Kume T, Kawamoto T, Okura H, Toyota E, Neishi Y, Watanabe N, Hayashida A, Okahashi N, Yoshimura Y, Saito K, et al. Local release of catecholamines from the hearts of patients with tako-tsubo-like left ventricular dysfunction. *Circ J*. 2008;72:106–108. doi: 10.1253/circj.72.106
77. Mori H, Ishikawa S, Kojima S, Hayashi J, Watanabe Y, Hoffman JL, Okino H. Increased responsiveness of left ventricular apical myocardium to adrenergic stimuli. *Cardiovasc Res*. 1993;27:192–198. doi: 10.1093/cvr/27.2.192
78. Akashi YJ, Nakazawa K, Sakakibara M, Miyake F, Musha H, Sasaka K. 123I-MIBG myocardial scintigraphy in patients with “takotsubo” cardiomyopathy. *J Nucl Med*. 2004;45:1121–1127.
79. Mizutani K, Shiota A, Hirose Y, Saito R, Yamada S. Serious takotsubo cardiomyopathy: an autopsy case presenting severe irreversible myocardial damage after frequent episodes of recurrence. *Diagn Pathol*. 2020;15:90. doi: 10.1186/s13000-020-01006-x
80. Nef HM, Möllmann H, Troldl C, Kostin S, Voss S, Hilpert P, Behrens CB, Rolf A, Rixe J, Weber M, et al. Abnormalities in intracellular Ca²⁺ regulation contribute to the pathomechanism of Tako-Tsubo cardiomyopathy. *Eur Heart J*. 2009;30:2155–2164. doi: 10.1093/eurheartj/ehp240
81. Couch LS, Fiedler J, Chick G, Clayton R, Dries E, Wienecke LM, Fu L, Fourre J, Pandey P, Derda AA, et al. Circulating microRNAs predispose to takotsubo syndrome following high-dose adrenaline exposure. *Cardiovasc Res*. 2021;cvab210. doi: 10.1093/cvr/cvab210
82. Jaguszewski M, Osipova J, Ghadri JR, Napp LC, Widera C, Franke J, Fijalkowski M, Nowak R, Fijalkowska M, Volkmann I, et al. A signature of circulating microRNAs differentiates takotsubo cardiomyopathy from acute myocardial infarction. *Eur Heart J*. 2014;35:999–1006. doi: 10.1093/eurheartj/ehs392
83. Ancona F, Bertoldi LF, Ruggieri F, Cerri M, Magnoni M, Beretta L, Cianflone D, Camici PG. Takotsubo cardiomyopathy and neurogenic stunned myocardium: similar albeit different. *Eur Heart J*. 2016;37:2830–2832. doi: 10.1093/eurheartj/ehw035
84. Templin C, Hänggi J, Klein C, Topka MS, Hiestand T, Levinson RA, Jurisic S, Lüscher TF, Ghadri JR, Jäncke L. Altered limbic and autonomic processing supports brain-heart axis in Takotsubo syndrome. *Eur Heart J*. 2019;40:1183–1187. doi: 10.1093/eurheartj/ehz068
85. Radfar A, Abohashem S, Osborne MT, Wang Y, Dar T, Hassan MZO, Ghoneem A, Naddaf N, Patrich T, Abbasi T, et al. Stress-associated neurobiological activity associates with the risk for and timing of subsequent takotsubo syndrome. *Eur Heart J*. 2021;42:1898–1908. doi: 10.1093/eurheartj/ehab029
86. Miyake R, Ohtani K, Hashimoto T, Yada R, Sato T, Shojima Y, Hayashidani S, Higo T, Tsutsui H. Takotsubo syndrome in a heart transplant recipient with poor cardiac sympathetic reinnervation. *ESC Heart Fail*. 2020;7:1145–1149. doi: 10.1002/ehf2.12632
87. Rivero F, Cuesta J, García-Guimaraes M, Bastante T, Alvarado T, Antuña P, Alfonso F. Time-related microcirculatory dysfunction in patients with takotsubo cardiomyopathy. *JAMA Cardiol*. 2017;2:699–700. doi: 10.1001/jamacardio.2016.5993
88. Komesaroff PA, Esler MD, Sudhir K. Estrogen supplementation attenuates glucocorticoid and catecholamine responses to mental stress in perimenopausal women. *J Clin Endocrinol Metab*. 1999;84:606–610. doi: 10.1210/jcem.84.2.5447
89. Möller C, Stiermaier T, Meusel M, Jung C, Graf T, Eitel I. Microcirculation in patients with takotsubo syndrome—the prospective CIRCUS-TTS study. *J Clin Med*. 2021;10:2127. doi: 10.3390/jcm10102127
90. Godsman N, Kohlhaas M, Nickel A, Cheyne L, Mingarelli M, Schweiger L, Hepburn C, Munts C, Welch A, Delibegovic M, et al. Metabolic alterations in a rat model of takotsubo syndrome. *Cardiovasc Res*. 2021. doi: 10.1093/cvr/cvab081
91. Wittstein IS. Why age matters in takotsubo syndrome. *J Am Coll Cardiol*. 2020;75:1878–1881. doi: 10.1016/j.jacc.2020.03.030
92. Dawson DK, Neil CJ, Henning A, Cameron D, Jagpal B, Bruce M, Horowitz J, Frenneaux MP. Tako-tsubo cardiomyopathy: a heart stressed out of energy? *JACC Cardiovasc Imaging*. 2015;8:985–987. doi: 10.1016/j.jcmg.2014.10.004
93. Wilson HM, Cheyne L, Brown PAJ, Kerr K, Hannah A, Srinivasan J, Duniak N, Horgan G, Dawson DK. Characterization of the myocardial inflammatory response in acute stress-induced (takotsubo) cardiomyopathy. *JACC Basic Transl Sci*. 2018;3:766–778. doi: 10.1016/j.jaccbts.2018.08.006
94. Neil C, Nguyen TH, Kucia A, Crouch B, Sverdlow A, Chirkov Y, Mahadavan G, Selvanayagam J, Dawson D, Beltrame J, et al. Slowly resolving global myocardial inflammation/oedema in Tako-Tsubo cardiomyopathy: evidence from T2-weighted cardiac MRI. *Heart*. 2012;98:1278–1284. doi: 10.1136/heartjnl-2011-301481
95. Ong GJ, Nguyen TH, Stansborough J, Surikow S, Mahadavan G, Worthley M, Horowitz J. The N-Acetylcysteine and Ramipril in Takotsubo Syndrome Trial (NACRAM): Rationale and design of a randomised controlled trial of sequential N-acetylcysteine and ramipril for the management of takotsubo syndrome. *Contemp Clin Trials*. 2020;90:105894. doi: 10.1016/j.cct.2019.105894
96. Anker SD, Butler J, Filippatos G, Khan MS, Marx N, Lam CSP, Schnaidt S, Ofstad AP, Brueckmann M, Jamal W, et al. Effect of empagliflozin on cardiovascular and renal outcomes in patients with heart failure by baseline diabetes status: results from the EMPEROR-Reduced Trial. *Circulation*. 2021;143:337–349. doi: 10.1161/CIRCULATIONAHA.120.051824
97. Packer M, Anker SD, Butler J, Filippatos G, Pocock SJ, Carson P, Januzzi J, Verma S, Tsutsui H, Brueckmann M, et al. Cardiovascular and renal outcomes with empagliflozin in heart failure. *N Engl J Med*. 2020;383:1413–1424. doi: 10.1056/NEJMoa2022190